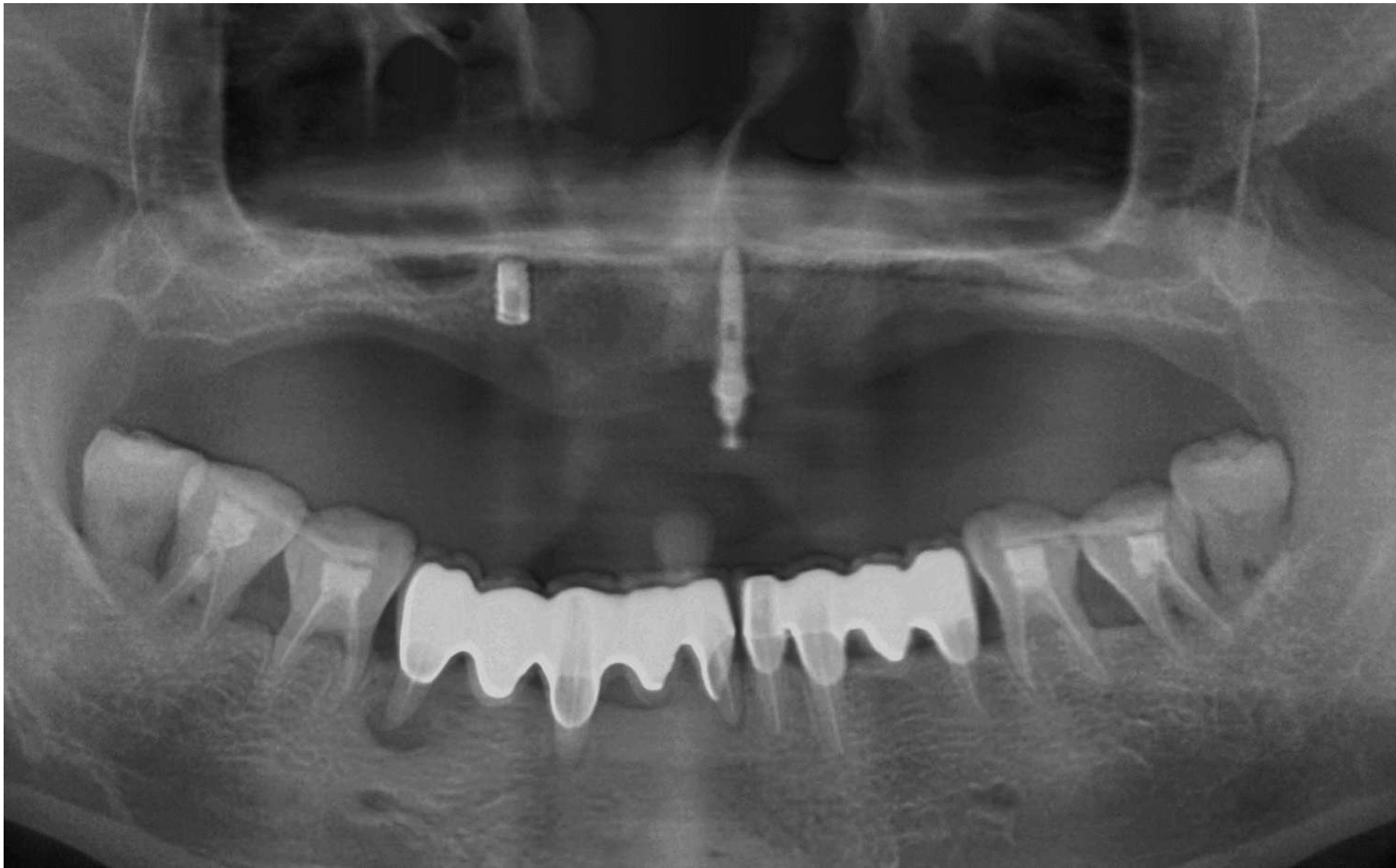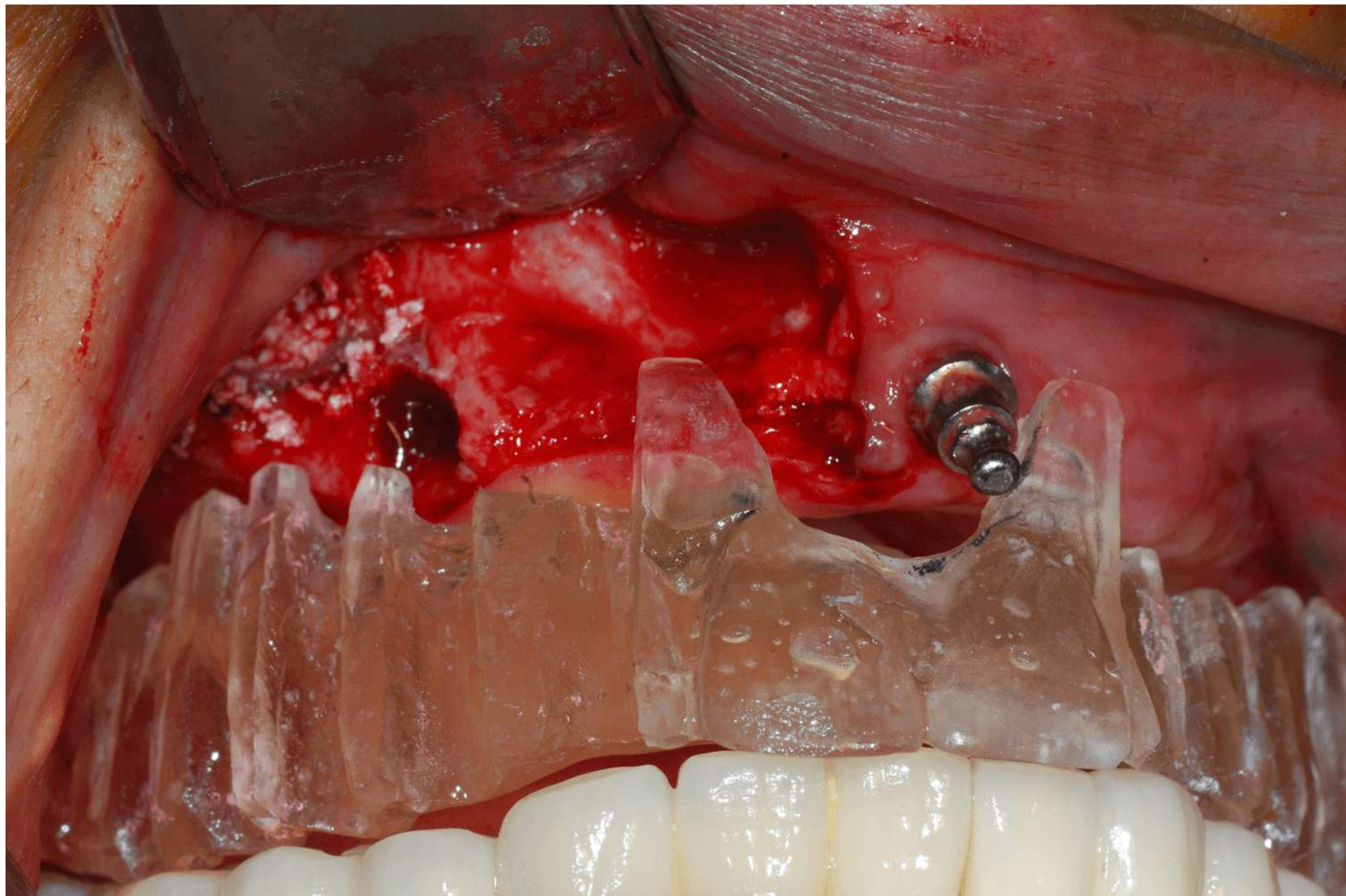
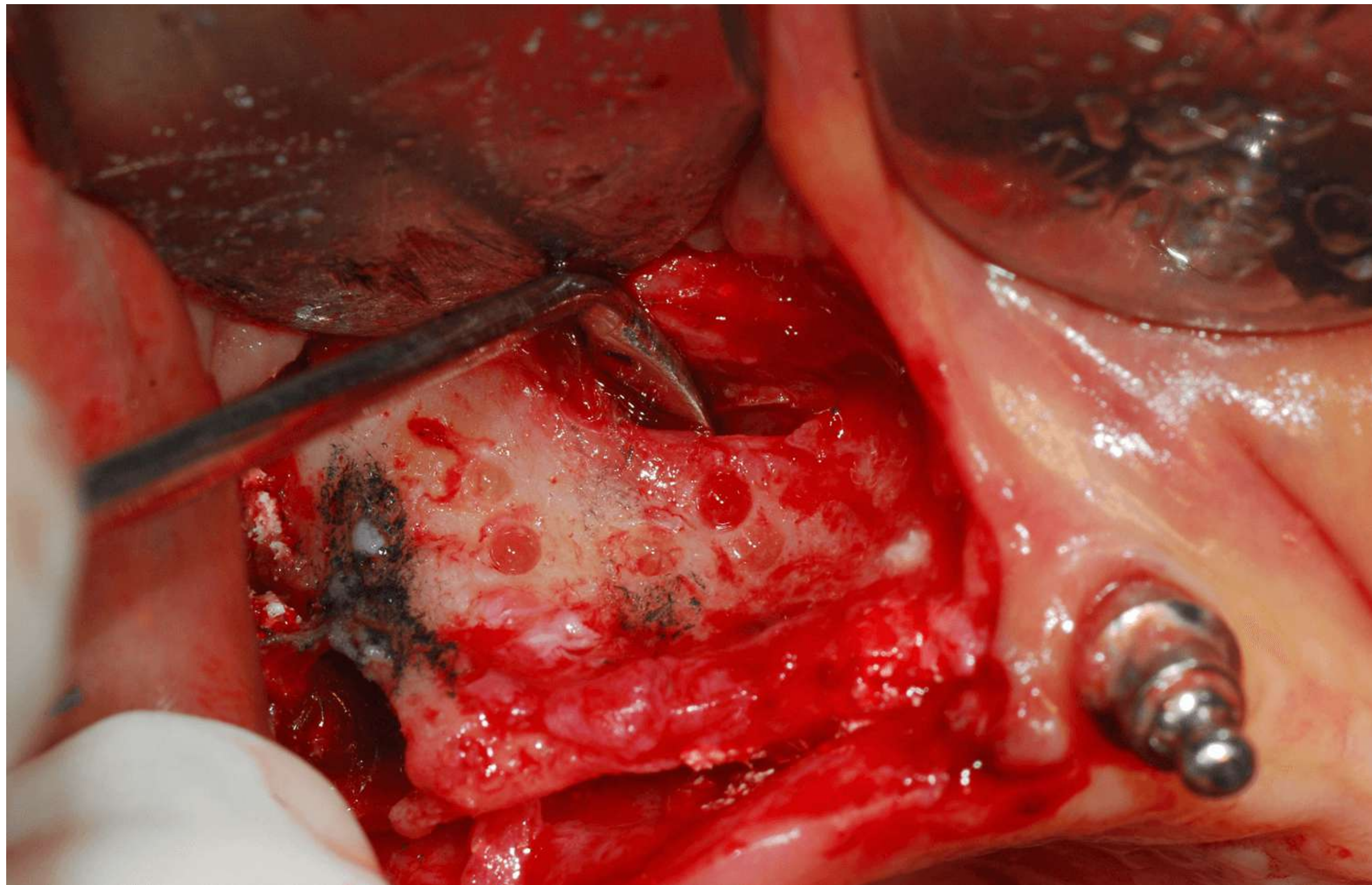


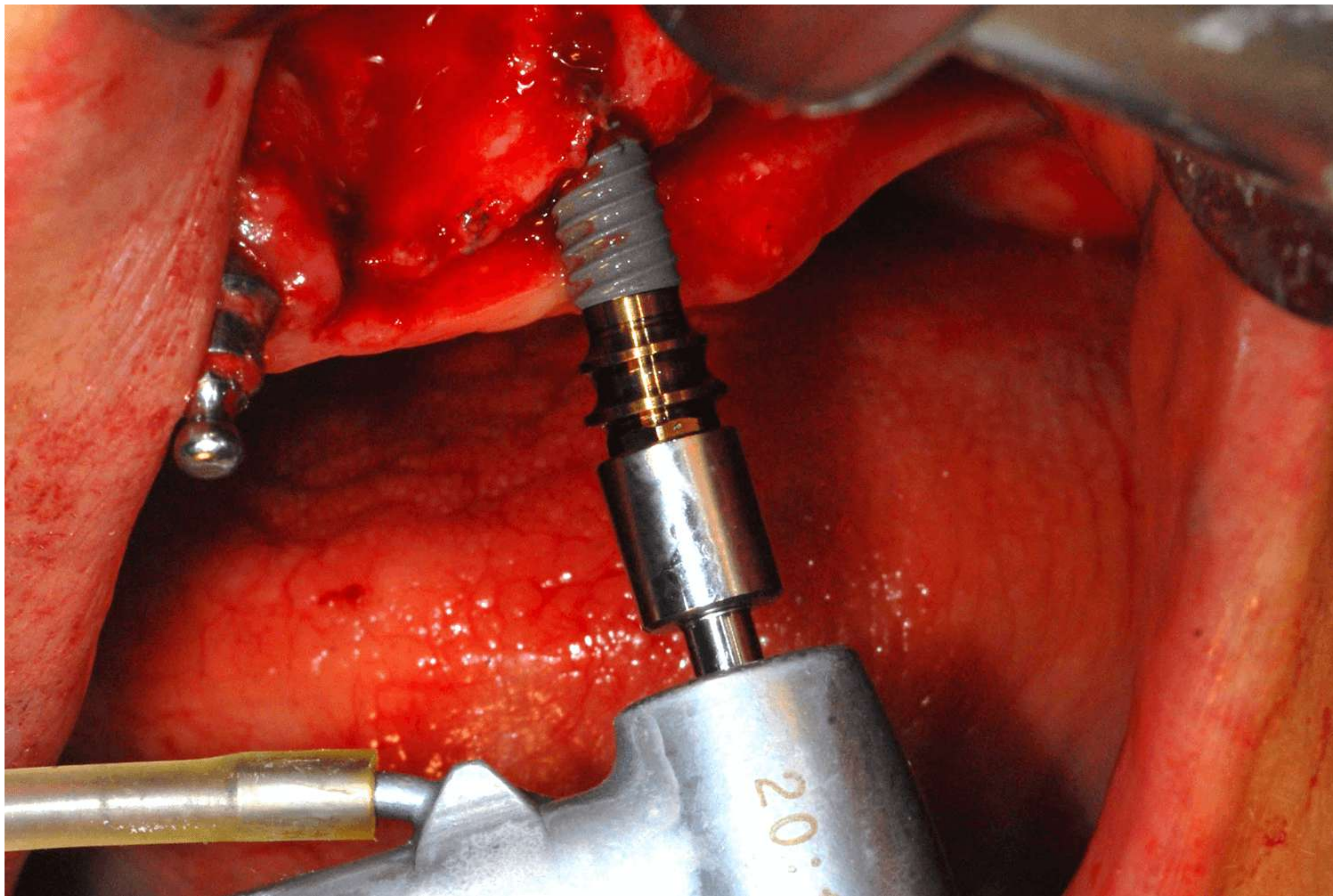
Highly resorbed maxillary alveolar ridge and unstable mandibular periodontal condition



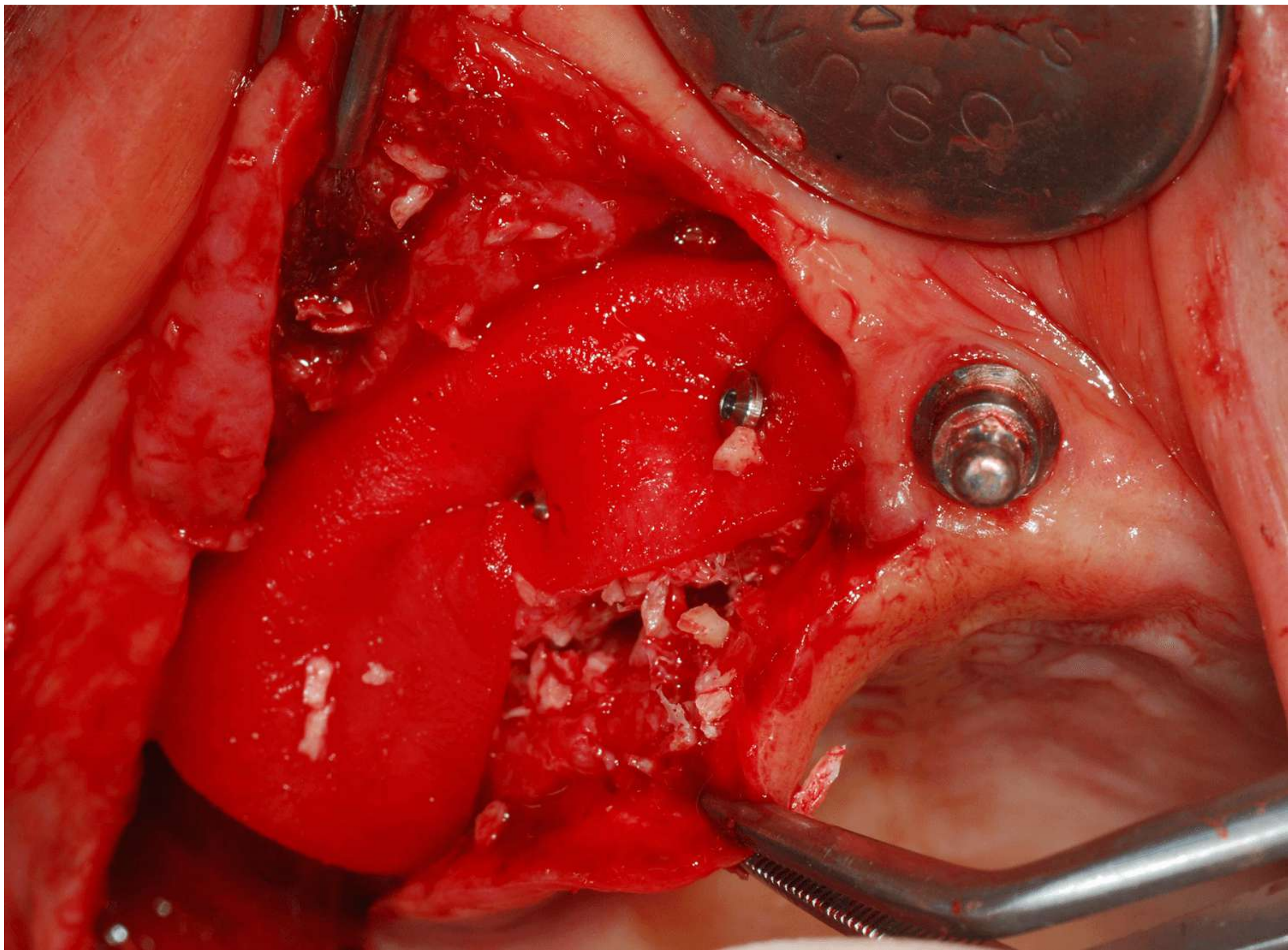
Horizontal and vertical ridge resorption relating to the surgical stent



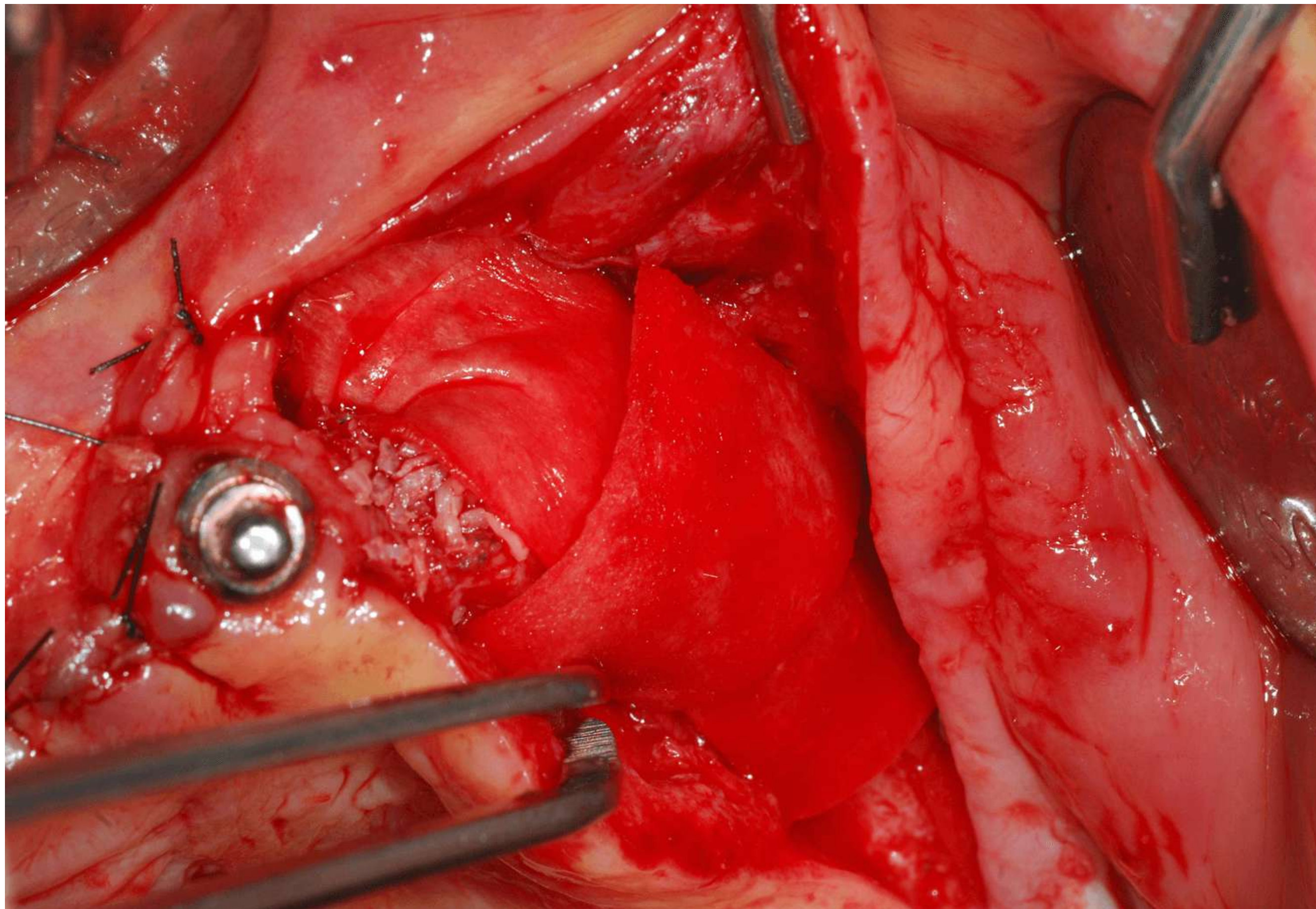
Nasal mucosa was elevated for fixture installation



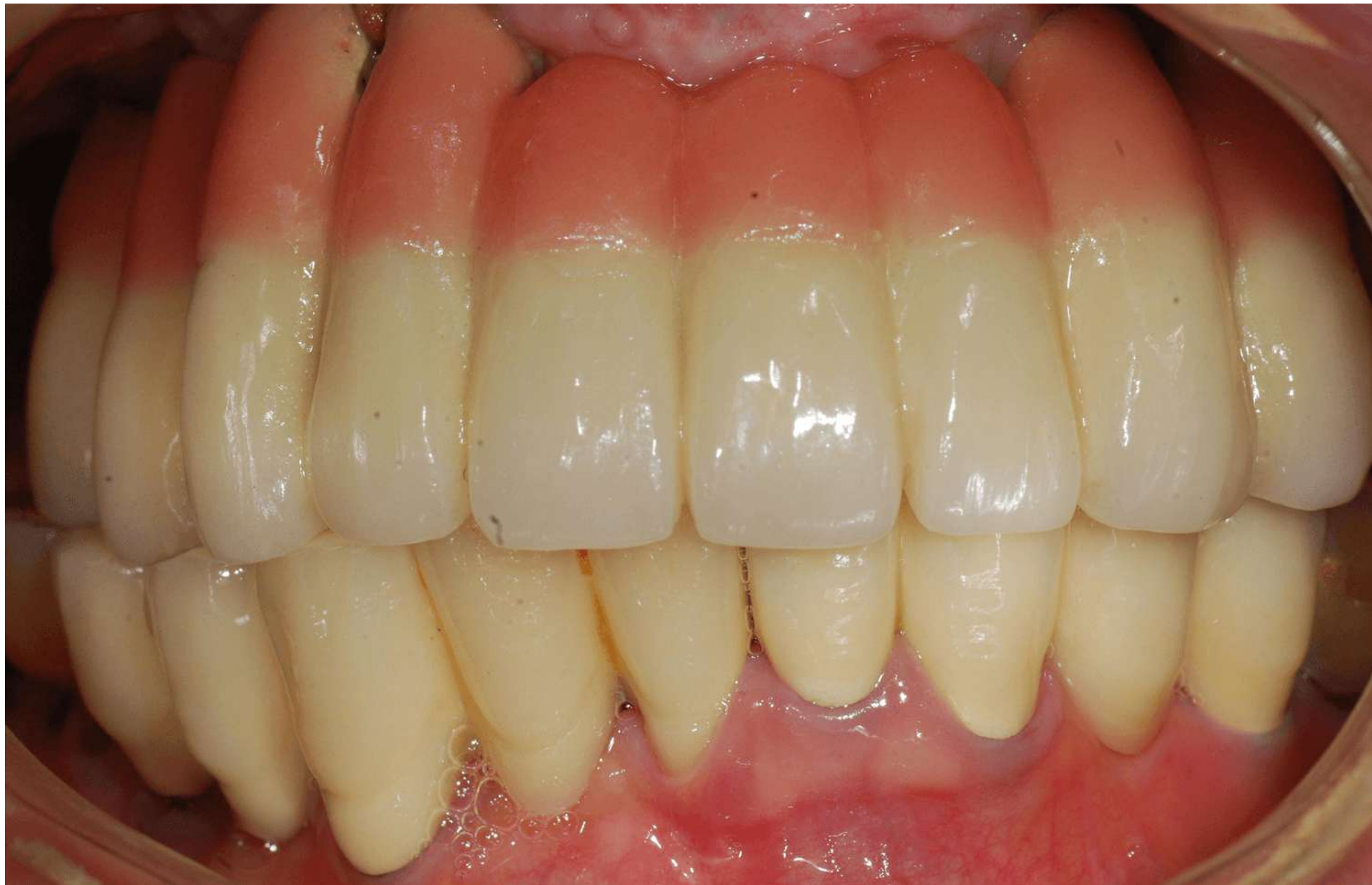A total of 10 Ca Sa fixtures were installed with GBR and bilateral sinus graft



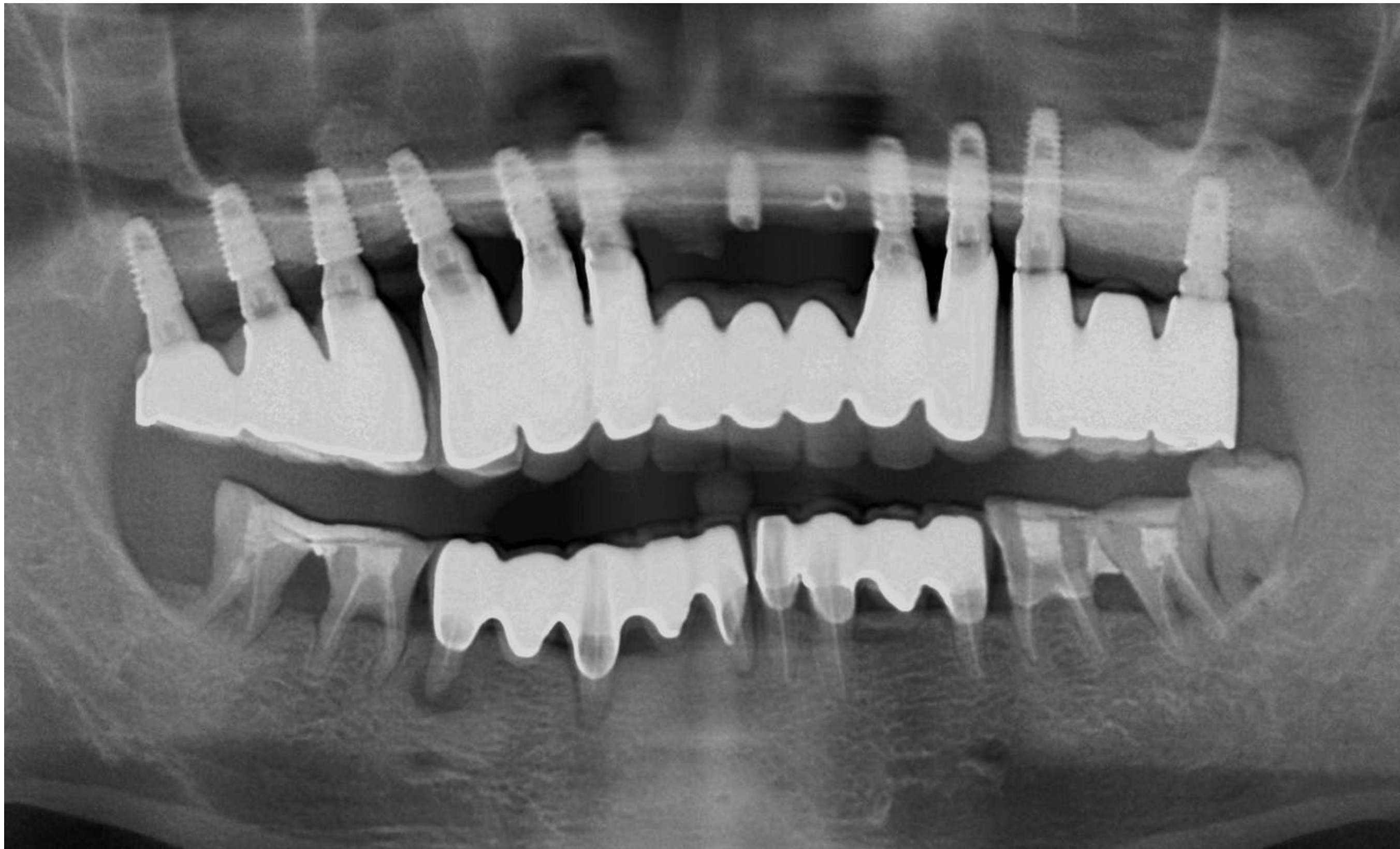
Maxilla allograft was performed using a 50:50 mixture of InterOss® and allograft.



The right maxillary sinus was grafted with BoneSigma™BSCP and the left maxillary sinus was grafted with InterOss®



Pink porcelain was used to compensate the vertically resorbed alveolar bone ridge



X-ray at 2 years shows a stable state even with an unfavorable crown-implant ratio