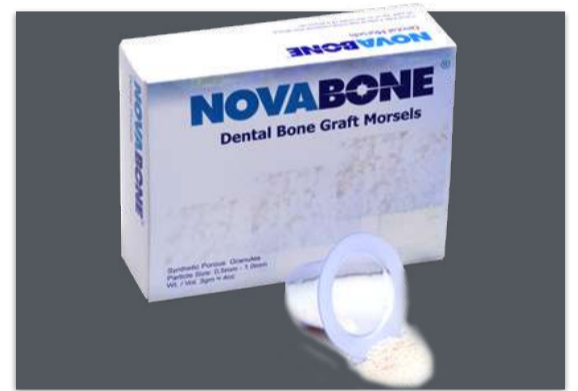

# NOVABONE

Proven to Signal, Recruit, Proliferate, and Differentiate.

## NOVABONE® MORSELS

### CLINICAL CASES

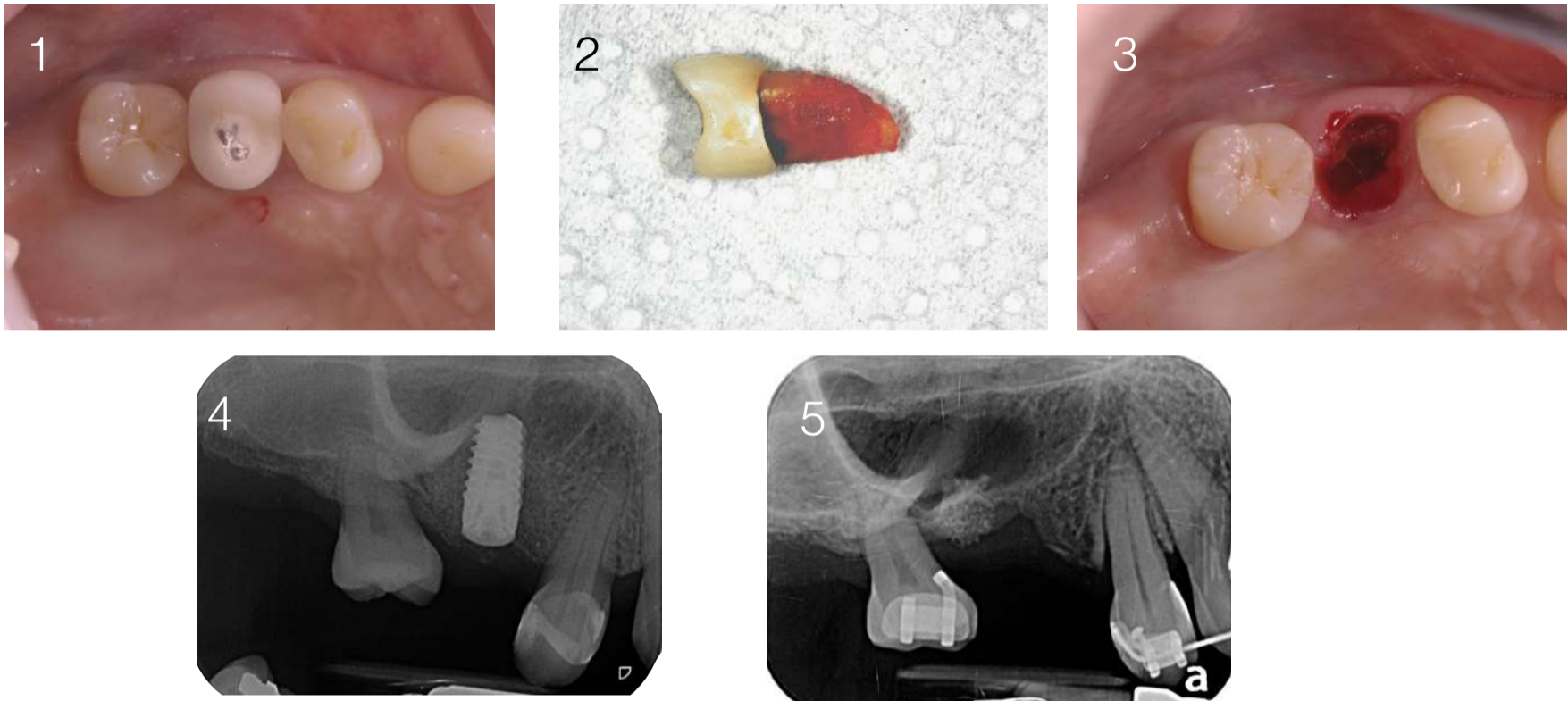


- DDS-National University of Colombia.
- Specialist in Audiovisual pedagogy - El Bosque University.
- Master in Comprehensive Dentistry in adult (Prosthodontics-Periodontics) - University of Antioquia.
- Titular Professor Faculty of Dentistry University of Antioquia.
- Member active Colombian Association of periodontal and Osseo integration.
- Publications author of scientific articles in the areas of Prosthodontics, Periodontics and Dental Implants
- International lecturer.

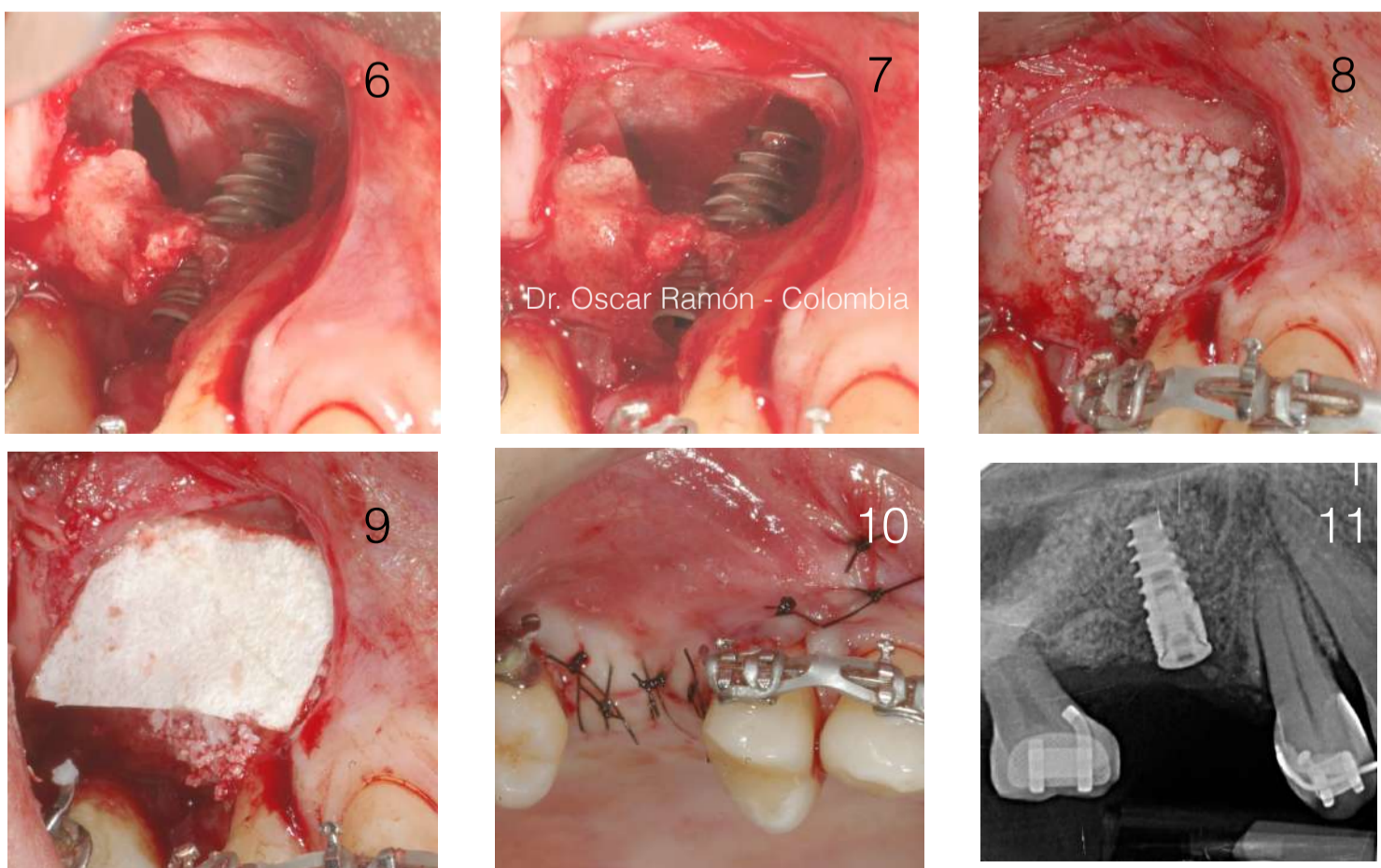
# SINUS LIFT AND BONE GRAFT

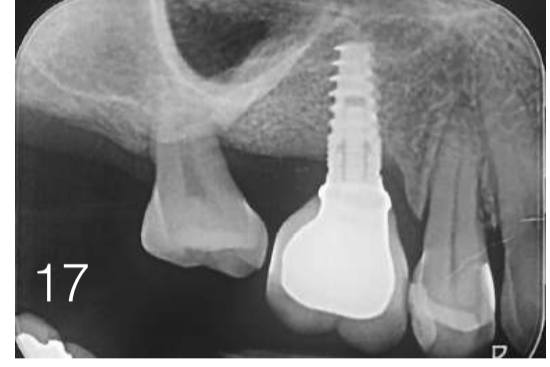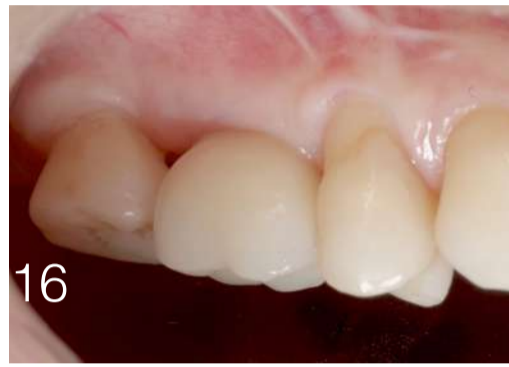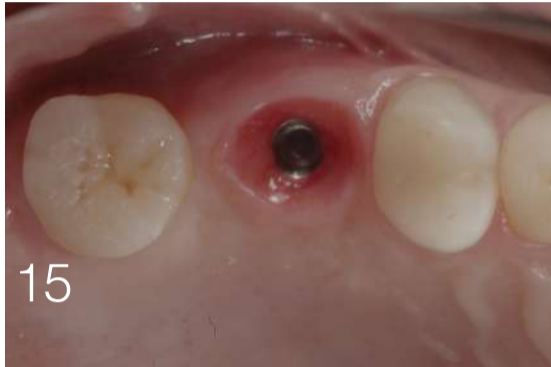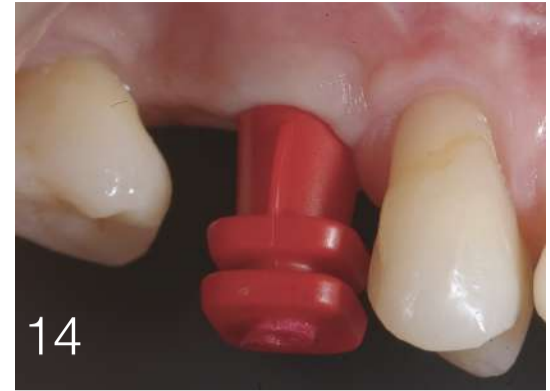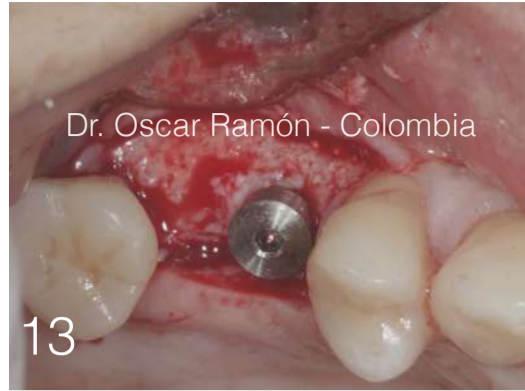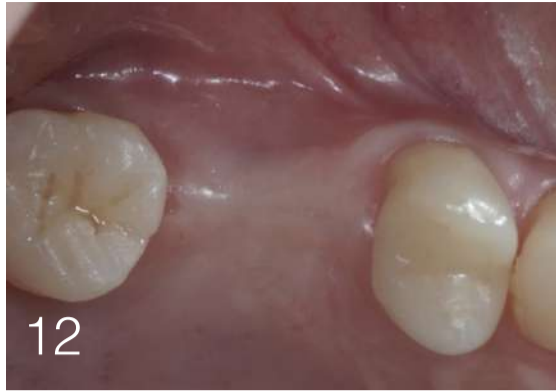## Case 1:

51 years old female patient lost tooth number 15 for endodontic and periodontal reasons (Fig 1, 2, and 3). Two months after the extraction and implant with sinus elevation was performed (Fig 4). The implant failed after 4 months. The site cleaned and the patient wait two months to repeat the tratment (Fig 5). Orthodontic tratment was done to distrubute the spaces and to improve the oclusion.



The site was reopened and the sinus elevation the membrane was perforated. One Dynamix Implant (Cortex Dental Ind.) was estabilized usin a small piece of native bone. (fig 6). The membrane was repaired with a collagen membrane (Fig 7) and Novabone Morsels (NovaBone Products) was used for bone regeneration (Fig 8). A collagen membrane (3Biomat Inc.) was used to protect the bone and the flap was sutured (Fig 9 and 10). Control Rx was done (Fig 11).





After the healing time the site was re-opened and a 3mm healing cap was used (Fig 12 and 13). An impression was taken using the snap technique (Fig 14) and a tissue profile was created with a temporary restoration (fig 15). Final restoration and control Rx after two years of follow-up (Fig 16 and 17).