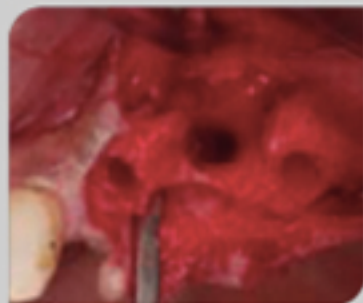
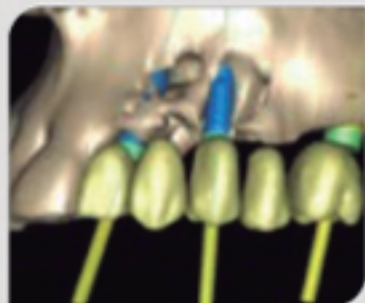
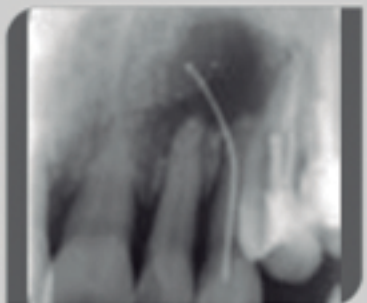
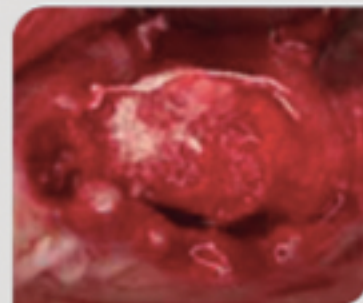


ROG con aloinjerto esponjoso particulado y membrana no reabsorbible con colocación de implantes

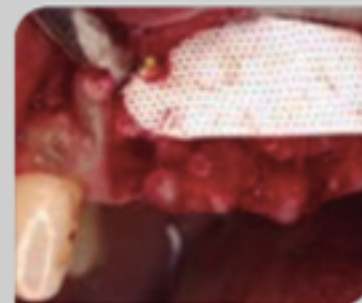
Dr. Pablo Tejerina, Gijón



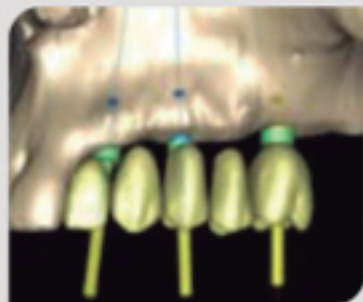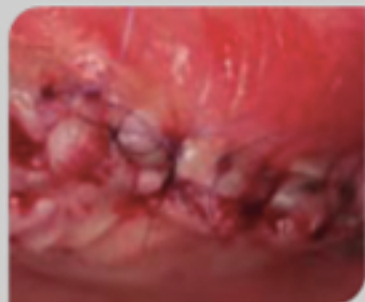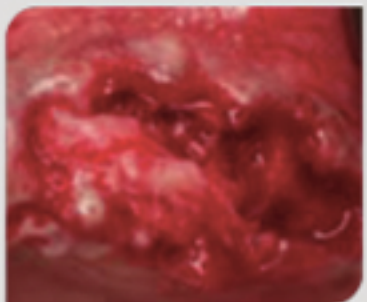
Exodoncia de dientes con legrado del lecho



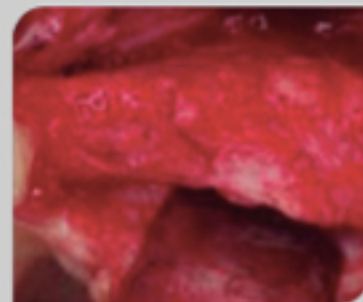
Regeneración ósea guiada con aloinjerto esponjoso



Membrana no reabsorbible Cytoplast™



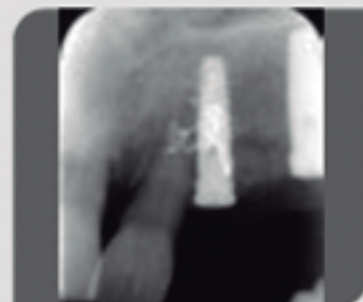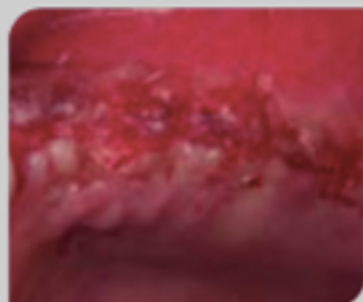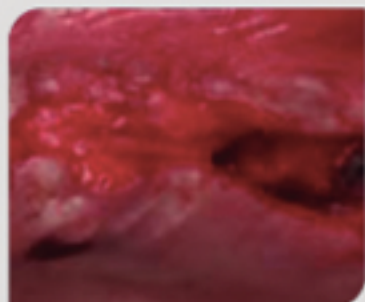
CBCT Siplant superior



4 meses después



Reentrada y colocación implantes s los 15 días



Control radiológico



Control radiológico