

See discussions, stats, and author profiles for this publication at: <https://www.researchgate.net/publication/273155920>

# Reconstruction of an Atrophied Posterior Mandible with the Inlay Technique and Allograft Block Versus Allograft Particulate: A Case Report

ARTICLE in THE INTERNATIONAL JOURNAL OF PERIODONTICS & RESTORATIVE DENTISTRY · MARCH 2015

Impact Factor: 1.42 · DOI: 10.11607/prd.2099 · Source: PubMed

---

READS

49

## 4 AUTHORS:



**Vittorio Checchi**

Università degli Studi di Trieste

53 PUBLICATIONS 340 CITATIONS

SEE PROFILE



**Annalisa Mazzoni**

Università degli Studi di Trieste

109 PUBLICATIONS 3,429 CITATIONS

SEE PROFILE



**Lorenzo Breschi**

University of Bologna

368 PUBLICATIONS 6,710 CITATIONS

SEE PROFILE



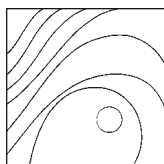
**Pietro Felice**

University of Bologna

103 PUBLICATIONS 1,655 CITATIONS

SEE PROFILE

# Reconstruction of an Atrophied Posterior Mandible with the Inlay Technique and Allograft Block Versus Allograft Particulate: A Case Report



Vittorio Checchi, DDS, PhD<sup>1</sup>  
 Annalisa Mazzoni, DDS, PhD<sup>1</sup>  
 Lorenzo Breschi, DDS, PhD<sup>2</sup>  
 Pietro Felice, MD, DDS, PhD<sup>3</sup>

*This case report describes the bilateral reconstruction of a severely atrophic posterior mandible in a 30-year-old woman using allograft block versus particulate grafting in the inlay technique. Three months later, four dental implants were placed and bone core biopsy specimens were taken for histologic evaluation. During implant placement, the grafted sites were stable with good clinical osseointegration. The histologic analysis showed the presence of compact bone revealing areas of demarcation between grafted bone, newly formed bone, and bone-regenerated areas. Allografts might serve as an alternative to autogenous and heterologous grafting in posterior mandible augmentation using the inlay technique. (Int J Periodontics Restorative Dent 2015;35:e20–e27. doi: 10.11607/prd.2099)*

A variety of preprosthetic augmentation procedures have been developed for the atrophic posterior mandible to overcome problems mainly related to the surface transposition of the inferior alveolar nerve and the augmented interarch occlusal distance.

The inlay bone graft technique, first described by Schettler in 1976,<sup>1</sup> was recently applied in the posterior mandible with remarkable results in terms of vertical bone augmentation.<sup>2–4</sup> In order to avoid donor site morbidity and patient complaints, some authors<sup>2,5–8</sup> promoted the use of inorganic bovine bone blocks as inlay bone grafts, showing clinical and histologic outcomes comparable to those achieved with the use of autogenous bone blocks. Despite these promising results, however, the use of inorganic bovine bone grafts has been associated with the persistence of residuals in association with an extreme fragility of the block responsible out of concern for the difficult handling of the graft.<sup>7</sup>

To the best of the authors' knowledge, there is no evidence regarding the use of allografts for the inlay technique in the literature; they

<sup>1</sup>Researcher, Department of Medical Sciences, University of Trieste, Trieste, Italy.

<sup>2</sup>Professor, Department of Biomedical and Neuromotor Sciences—DIBINEM, University of Bologna, Bologna, Italy.

<sup>3</sup>Researcher, Department of Biomedical and Neuromotor Sciences—DIBINEM, University of Bologna, Bologna, Italy.

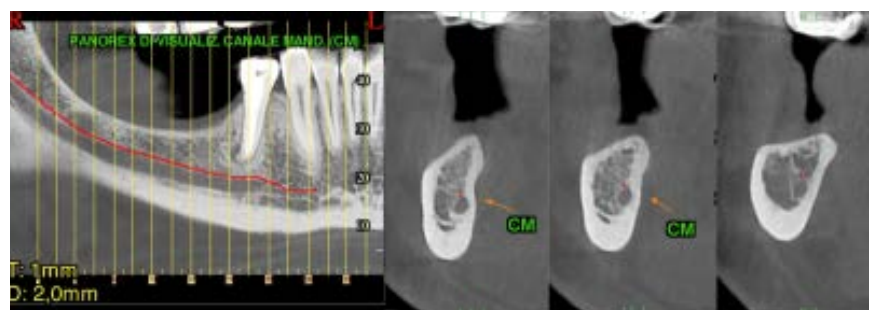
Correspondence to: Dr Vittorio Checchi, Department of Medical Sciences, University of Trieste, Italy, Ospedale Maggiore, Piazza dell'Ospitale 2, 34125 Trieste, Italy; email: vchecchi@units.it.

©2015 by Quintessence Publishing Co Inc.

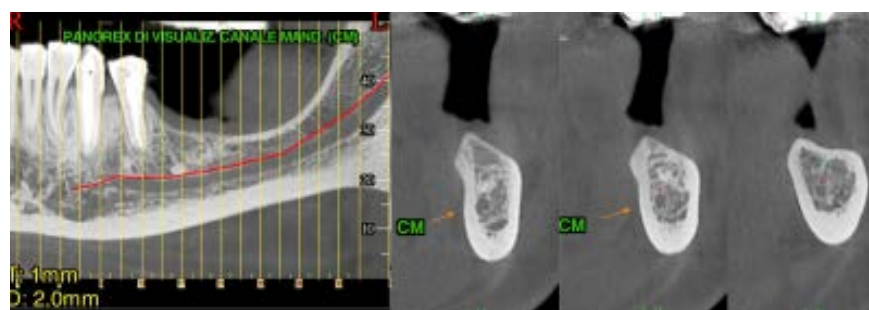
have been previously proposed only for onlays or veneers.<sup>9,10</sup> This case report describes an inlay augmentation procedure devised to allow implant-supported prosthetic rehabilitation in the atrophic posterior mandible. In order to set up a randomized controlled trial (RCT) with a split-mouth design, the present pilot study aimed to conduct a preliminary test of the inlay technique to vertically increase an atrophic posterior mandible. Tested materials were an allograft block on one side and allograft particulate on the other side, with the purpose to assay the most effective graft procedure through clinical and histologic investigations.

## Case report

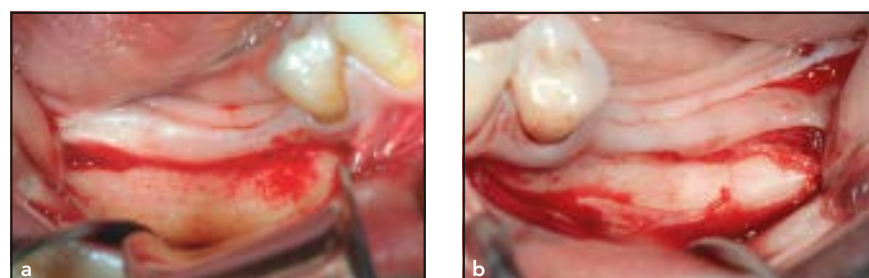
A 30-year-old woman requested fixed prosthetic rehabilitation of her bilateral posterior atrophic mandible and was referred to the Department of Periodontology and Implantology, University of Bologna, Bologna, Italy. The preoperative mean residual bone height above the mandibular canal was  $\leq 7$  (6.9) mm distal to the right mental nerve foramen (Fig 1) and  $\leq 8$  (7.1) mm distal to the left mental nerve foramen (Fig 2). After studying the case and evaluating all possible options for implant-supported rehabilitation, the patient declined rehabilitation with short implants and long prosthetic restorations due to her young age. Thus, a bilateral inlay augmentation procedure with implant placement in a stage-two surgery was chosen



**Fig 1** Computed tomography (CT) scan showing insufficient bone height over the right mandibular canal to place dental implants of adequate length.



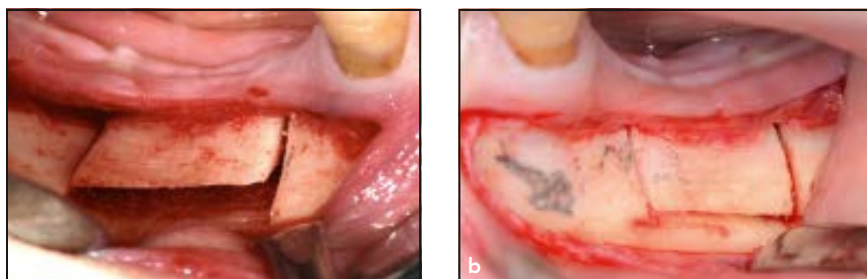
**Fig 2** CT scan showing insufficient bone height over the left mandibular canal to place dental implants of adequate length.



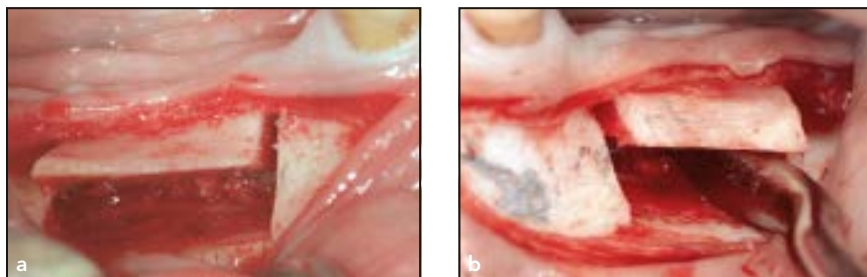
**Fig 3** Buccal bone plate exposure on the (a) right and (b) left side.

to allow for the planned mandibular prosthetic rehabilitation. However, since the patient declined intraoral autogenous bone harvesting, the inlay procedure required the use of an allograft block (OraGraft, LifeNet Health) on the left side and allograft particulate (OraGraft) on the right side. The patient gave written informed consent to the proposed treatment.

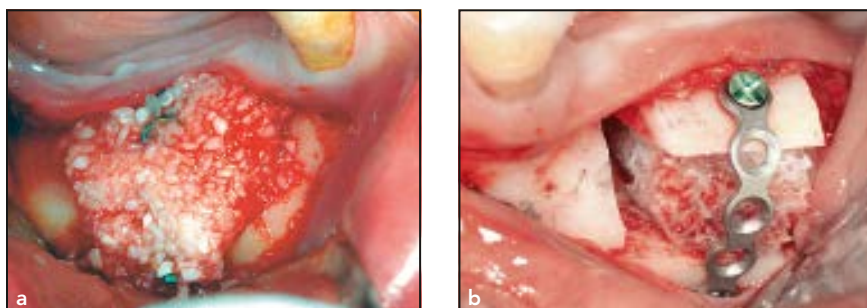
The surgical procedure was performed bilaterally under local anesthesia. The technique started on both sides with a paracrestal incision in the buccal vestibule, and the subperiosteal tissues were dissected carefully with no tension on the mental nerve (Fig 3). No mucoperiosteal dissection was performed toward the alveolar crest or on the lingual side. Three piezosurgical inserts



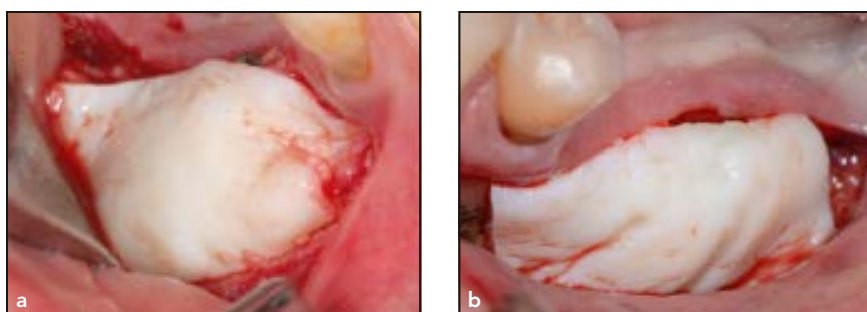
**Fig 4** Horizontal osteotomic cut, performed with a piezosurgical unit, on the (a) right and (b) left side.



**Fig 5** Osteotomized segment coronally elevated on the (a) right and (b) left side.



**Fig 6** Insertion of the grafts between the osteotomized cranial segment and the mandibular basal bone: (a) allograft particulate on the right side and (b) allograft bone block on the left side.



**Fig 7** Placement of a resorbable dermis membrane over the grafted areas.

(OT8R, OT8L, and OT7, Mectron Piezosurgery Device, Mectron) were

used to create a horizontal osteotomy at approximately 2 to 3 mm

above the mandibular canal with two oblique cuts: The mesial cut was made 2 mm distal to the emergence of the mental nerve, whereas the distal cut was made relative to the implant/graft treatment plane (Fig 4). The cranial segment was then moved upward, sparing the lingual periosteum (Fig 5). On the left mandible side, an allograft bone block (OraGraft) was fitted between the osteotomized cranial segment and the mandibular basal bone. A titanium miniplate was fixed with mini-screws (KLS Martin), and the gaps were filled with particulate derived from the bone block (Fig 6a). On the right mandible, the surgical team performed the same procedure, first stabilizing the segment with the titanium miniplate and then grafting the area with demineralized cancellous cortical bone particulate (OraGraft; Fig 6b). Resorbable decellularized dermis membranes (OraCell, LifeNet Health) were applied above the buccal surfaces of both surgical sites (Fig 7). After making periosteal-releasing incisions to obtain tension-free closure, the flaps were sutured carefully with Vicryl 4.0 (Ethicon FS-2).

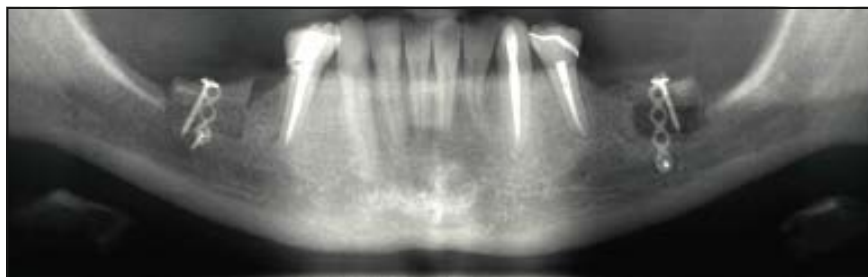
In combination with a nonsteroidal analgesic (Ketoprofen, Orudis, Aventis), antibiotic therapy (Amoxicillin with clavulanic acid; Augmentin, GlaxoSmithKline) was administered at a loading dose of 2 g, followed by 2 g per day for 10 days. Postsurgical instructions included soft-food diet for 2 weeks and appropriate oral hygiene, including twice daily rinsing with a 0.2% chlorhexidine digluconate mouthrinse (Corsodyl, GlaxoSmithKline). Sutures were removed 15 days postoperatively.



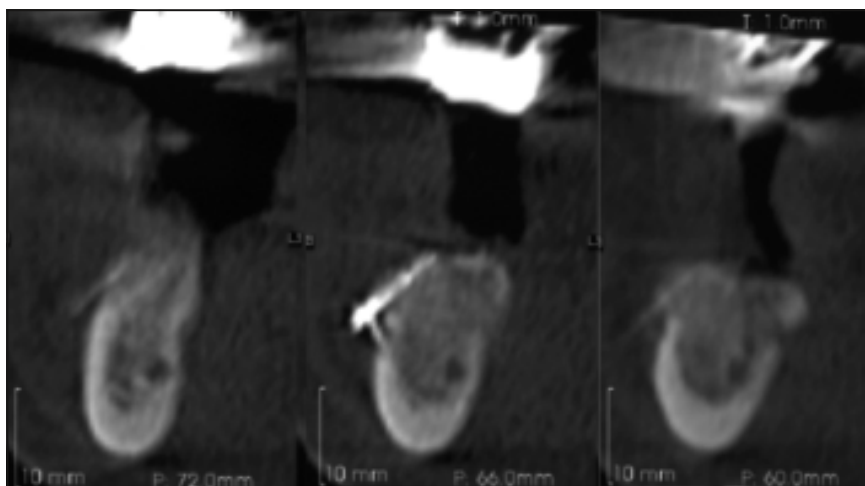
Patient recalls were set at 1 week after surgery, then twice in the first month and once in the following 3 months. Panoramic radiographic assessment was performed immediately (Fig 8), checking neurosensory function at each recall. No neurosensory disturbances were recorded.

### *Implant insertion*

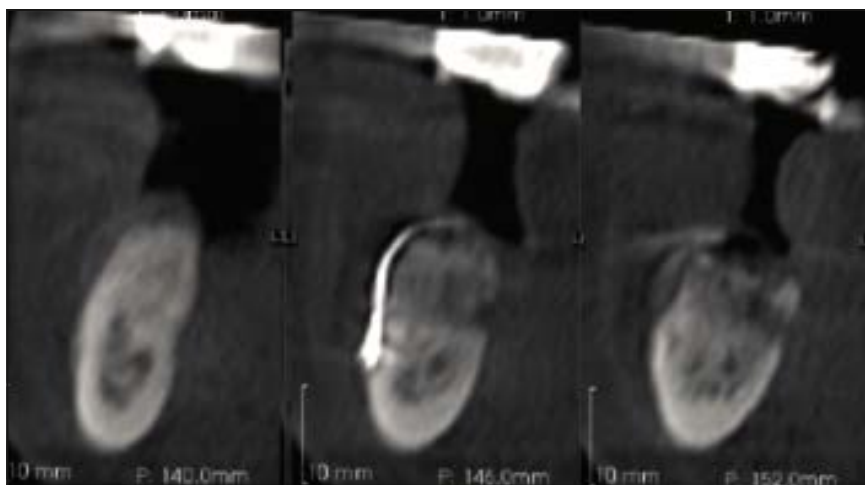
Three months after surgery, computed tomography (CT) scans showed a bilateral vertical height increase in the posterior mandible (Figs 9 and 10). Implants were then inserted under local anesthesia by the same surgeon. A full-thickness crestal incision was made, and the soft tissues overlying the reconstructed alveolar process were elevated in the posterior mandible bilaterally. The fixation miniscrews and miniplates used for the graft stabilization were removed, and endosseous implants were inserted. Four Shape1 implants (iRES) were placed in the grafted areas: two in the left side (3.75 mm in diameter and 10 mm long in the second premolar and the first molar) and two in the right side (two 3.75 mm in diameter and 8 mm long in the second premolar and the first molar). A bone trephine with an internal diameter of 2 mm was used as the second dental drill to take bone core biopsy specimens during implant site preparation of the mandibular left second premolar and mandibular right first molar. The flaps were sutured carefully with Vicryl 4.0 (Ethicon



**Fig 8** Postsurgical panoramic radiograph.



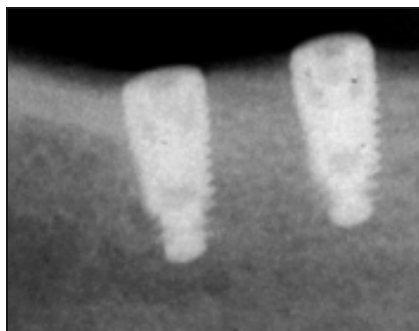
**Fig 9** CT scan taken before implant placement showing an adequate bone height over the right mandibular canal to place dental implants.



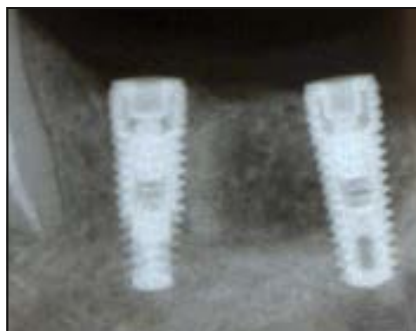**Fig 10** CT scan taken before implant placement showing an adequate bone height over the left mandibular canal to place dental implants.

FS-2). Periapical and panoramic radiographs were taken after implant

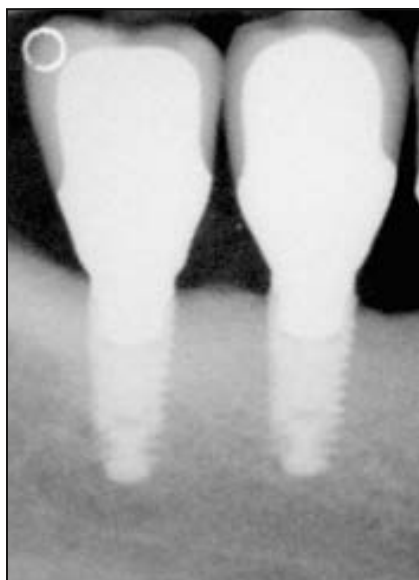insertion to verify the correct implant position (Figs 11 and 12).



**Fig 11** Periapical radiograph after implant insertion on the right side.

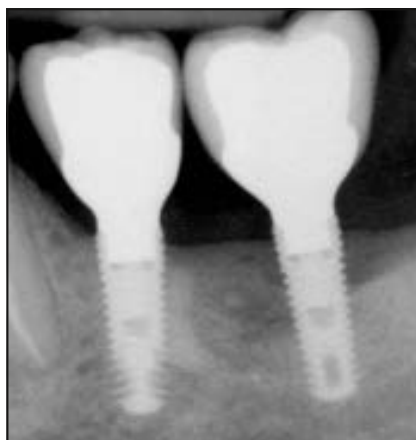

**Fig 12** Periapical radiograph after implant insertion on the left side.



**Fig 13** (left) Periapical radiograph after final prosthetic restoration on the right side.

**Fig 14** (below) Periapical radiograph after final prosthetic restoration on the left side.



Three grams of amoxicillin with clavulanic acid (Augmentin) were administered three times daily for 6 days, and an analgesic (Ketoprofen) was prescribed to be taken as needed. A cold/soft diet was recommended for 2 weeks together with appropriate oral hygiene, including twice daily rinsing with chlorhexidine digluconate mouth-rinse (Corsodyl). The sutures were removed 15 days after the surgical procedure. The patient was not allowed to wear removable dentures

before implant placement. The postoperative recovery was uneventful.

#### *Histologic evaluation*

The bone core biopsy specimens were immediately fixed in 10% buffered formalin solution (Sigma Chemical) at 4°C for 24 hours. The specimens were dehydrated in an ascending series of alcohols and embedded in a London White resin

(LR White Resin, London Resin). After resin polymerization, specimens were sectioned along their longitudinal axes using a high-precision diamond disk (Micromet, Remet) at 150  $\mu$ m and ground to approximately 40  $\mu$ m with a specially designed grinding machine (Micromet, Remet). The non-decalcified ground sections were stained with acid fuchsin and toluidine blue. The specimens were observed under normal transmitted light using an optical microscope (Nikon Eclipse, Nikon).

## **Results**

### *Clinical results*

The vertical bone height augmentation was evaluated 3 months after the inlay procedure, at the time of implant insertion, by comparing the paraxial 1-mm slices on the preoperative CT scans with those obtained just before implant insertion. Measurements were made on slices from 6, 12, and 18 mm posterior to the mental foramen, from the most coronal point of the mandibular canal to the intermediate point of the crestal ridge. The mean vertical bone gain after grafting and consolidation was 3.9 mm on the right mandible and 4.4 mm on the left side.

After 3 months from implant placement, the implants were restored with acrylic resin provisional single crowns. After another month, provisional restorations were replaced by definitive porcelain-fused-to-metal crowns (Figs 13 and 14).

### Histologic evaluation

Histologic analyses revealed that preexisting, compact, and mature bone was present at the bottom of the bone core biopsy specimens from both sides (Figs 15 and 16).

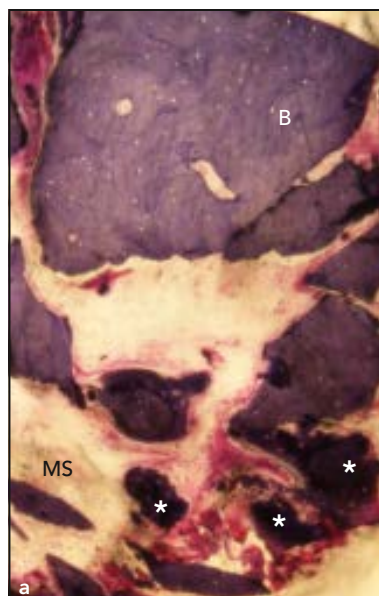Histologic evaluation of the bone core specimens taken from the right side, where allograft particulate was placed, showed the presence of persistent residual granules of the grafting material. Marrow spaces were present and delimited by small trabecular newly formed bone and portions of the graft. Mature cortical bone was observed at the bottom of the specimen (Fig 15).

From the allograft block side a tight connection between the grafted material and the preexisting basal bone was observed. Newly formed bone was seen in close contact with the block graft, with no intervening gaps or connective tissue at the interface (Fig 16).

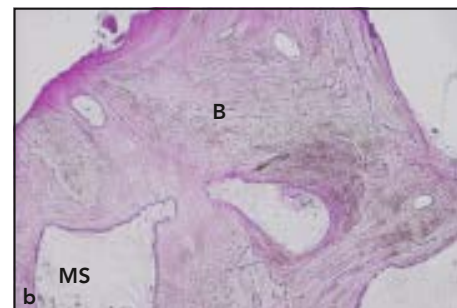
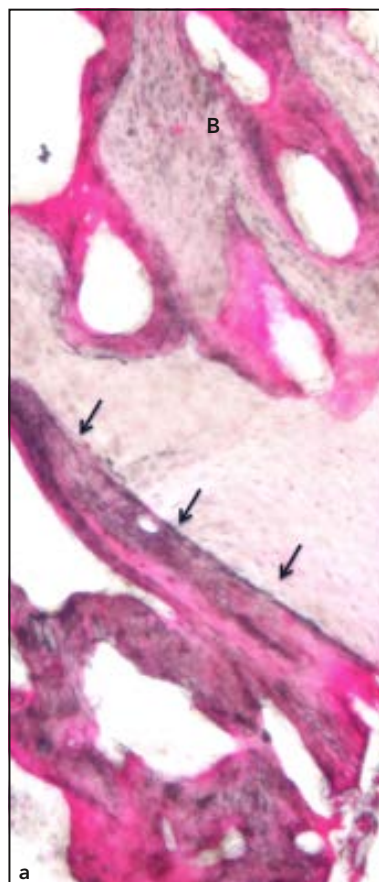
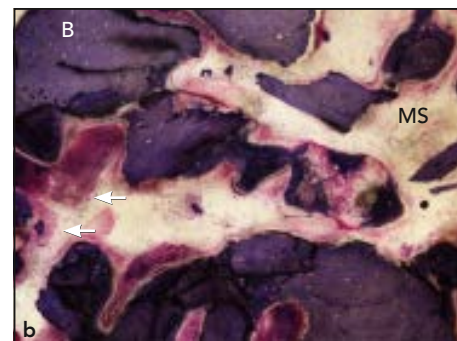
All histologic sections showed no sign of inflammation: No chronic inflammatory cell infiltrate or multinucleated giant cells were present (Figs 15 and 16).

### Discussion

Among grafting procedures, the inlay technique shows great potential for bone graft incorporation. As this procedure spares the lingual periosteum and maintains the blood supply, the final amount of bone resorption is lower, yielding high implant survival and success rates.<sup>11–14</sup> Inlay bone grafting in the posterior



**Fig 15** (a) Low-magnification view (×40) of the regenerated area showing remaining particles (asterisks) partially surrounded by newly formed bone. (b) Higher-magnification view (×100) showing particles and marrow spaces (MS) containing small newly formed vessels (white arrows), indicating intense angiogenesis (toluidine blue and acid fuchsin staining). B = bone.



**Fig 16** (a) Low-magnification view (×40) of the regenerated area showing a tight connection between the grafted material and the preexisting basal bone (black arrows). (b) Higher-magnification view (×100) showing the histologic aspect of the grafted area (toluidine-blue and acid fuchsin staining). B = bone; MS = marrow spaces.



mandible has, in fact, attained vertical bone gains of 4 to 8 mm post-operatively,<sup>2,3,12,15</sup> low complication rates,<sup>2-4</sup> low bone resorption before implant placement,<sup>3,12,15</sup> and reported success rates of at least 90%.<sup>3,4</sup>

In previous studies attempting to overcome the drawbacks of autogenous bone harvesting, which is invasive, time-consuming, technically demanding, and subject to complications, Stoelinga et al and Stellingsma et al<sup>11,13</sup> interposed a mixture of particulated autogenous bone and bone substitutes to augment the areas posterior to the mental foramen. More recently, Ewers et al<sup>16</sup> treated edentulous atrophic mandibles with the interpositional technique using porous algae-derived hydroxyapatite, and Choi et al<sup>12</sup> reported on the use of a bovine collagen matrix in the anterior interforaminal regions of nine mandibles treated with the inlay technique. No cases of allografts used in the inlay technique are reported in the literature, but several studies<sup>9,10,17</sup> have demonstrated that the use of the same material in the onlay technique of posterior mandibles results in a high rate of failures (70%), probably attributable to a compromised blood supply.<sup>18</sup>

This case report was conducted in order to understand which form of allograft could be more effective and easy to use in a future RCT. Clinical and histologic preliminary results of both block and particulate show similar findings, although the allograft block was much easier to handle. In fact, clinical handling of allograft particles was very demanding because, before placing

the particulate graft, the fixation to the basal bone of the osteotomized bony segment after its elevation is mandatory.<sup>19</sup> Thus, this procedure is time consuming, technique sensitive, and requires more effort than placing the block before fixing the bony segment. This clinical advantage is supported by the histologic results that have revealed the presence of newly formed bone at the graft interface and that the block graft appeared to be well incorporated with no adverse reactions.

The mean gain in mandibular bone height was 4.4 mm on the right and 3.9 mm on the left. The clinical and radiologic examinations at the time of implant placement showed no bone height reduction and no inflammatory symptoms or signs.

## Conclusions

The use of allogeneic bone can be considered a suitable material for bone regeneration in inlay grafting procedures when treating severe atrophy of the posterior mandible. According to the preliminary results, this material represents a good clinical alternative to autologous and inorganic bovine bone.

## Acknowledgments

The authors reported no conflicts of interest related to this study.

## References

1. Schettler D. Sandwich-technique with cartilage transplant for raising the alveolar process in the lower jaw [in German]. *Fortschr Kiefer Gesichtschir* 1976;20: 61–63.
2. Felice P, Marchetti C, Piattelli A, et al. Vertical ridge augmentation of the atrophic posterior mandible with interpositional bone grafts: Bone from the iliac crest versus bovine anorganic bone. *Eur J Oral Implantol* 2008;1:183–198.
3. Marchetti C, Trasarti S, Corinaldesi G, Felice P. Interpositional bone grafts in the posterior mandibular region: A report on six patients. *Int J Periodontics Restorative Dent* 2007;27:547–555.
4. Bianchi A, Felice P, Lizio G, Marchetti C. Alveolar distraction osteogenesis versus inlay bone grafting in posterior mandibular atrophy: A prospective study. *Oral Surg Oral Med Oral Pathol Oral Radiol Endod* 2008;105:282–292.
5. Felice P, Cannizzaro G, Checchi V, et al. Vertical bone augmentation versus 7-mm-long implants in posterior atrophic mandibles. Results of a randomised controlled clinical trial of up to 4 months after loading. *Eur J Oral Implantol* 2009; 2:7–20.
6. Felice P, Pellegrino G, Checchi L, Pistilli R, Esposito M. Vertical augmentation with interpositional blocks of anorganic bovine vs. 7-mm-long implants in posterior mandibles: 1-year results of a randomized clinical trial. *Clin Oral Implants Res* 2010;21:1394–1403.
7. Felice P, Marchetti C, Iezzi G, et al. Vertical ridge augmentation of the atrophic posterior mandible with interpositional bloc grafts: Bone from the iliac crest versus bovine anorganic bone. Clinical and histologic results up to 1 year after loading from a randomized controlled clinical trial. *Clin Oral Implants Res* 2009; 20:1386–1393.
8. Felice P, Checchi V, Pistilli R, Scarano A, Pellegrino G, Esposito M. Bone augmentation versus 5-mm dental implants in posterior atrophic jaws. Four-month post-loading results from a randomised controlled clinical trial. *Eur J Oral Implantol* 2009;2:267–281.



9. Waasdorp J, Reynolds MA. Allogenic bone onlay graft for alveolar ridge augmentation: A systematic review. *Int J Oral Maxillofac Implants* 2010;25: 525–531.
10. Chaushu G, Mardinger O, Peleg M, Ghelfan O, Nissan J. Analysis of complications following augmentation with cancellous block allografts. *J Periodontol* 2010;81:1759–1764.
11. Stellingsma C, Raghoobar GM, Meijer HJ, Batenburg RH. Reconstruction of the extremely resorbed mandible with interposed bone grafts and placement of endosseous implants. A preliminary report on outcome of treatment and patients' satisfaction *Br J Oral Maxillofac Surg* 1998;36:290–295.
12. Choi BH, Lee SH, Huh JY, Han SG. Use of the sandwich osteotomy plus an interpositional allograft for vertical augmentation of the alveolar ridge. *J Craniomaxillofac Surg* 2004;32:51–54.
13. Stoelinga PJ, Blijdorp PA, Ross RR, De Koomen HA, Huybers TJ. Augmentation of the atrophic mandible with interposed bone graft and particulate hydroxyapatite. *J Oral Maxillofac Surg* 1986;44: 353–360.
14. Felice P, Pistilli R, Marchetti C, et al. Reconstruction of atrophied anterior mandible with an inlay technique and resorbable miniplates: A case report. *Implant Dent* 2011;20:262–266.
15. Felice P, Pistilli R, Lizio G, Pellegrino G, Nisii A, Marchetti C. Inlay versus onlay iliac bone grafting in atrophic posterior mandible: A prospective controlled trial for the comparison of two techniques. *Clin Implant Dent Relat Res* 2009;11 (suppl 1):e69–e82.
16. Ewers R, Fock N, Millesi-Schobel G, Enislidis G. Pedicled sandwich plasty: A variation on alveolar distraction for vertical augmentation of the atrophic mandible. *Br J Oral Maxillofac Surg* 2004; 42:445–447.
17. Keith JD Jr, Petrungaro P, Leonetti JA, et al. Clinical and histologic evaluation of a mineralized block allograft: Results from the developmental period (2001–2004). *Int J Periodontics Restorative Dent* 2006; 26:321–327.
18. Bahat O, Fontanesi FV. Complications of grafting in the atrophic edentulous or partially edentulous jaw. *Int J Periodontics Restorative Dent* 2001;21:487–495.
19. Felice P, Lizio G, Marchetti C, Checchi L, Scarano A. Magnesium-substituted hydroxyapatite grafting using the vertical inlay technique. *Int J Periodontics Restorative Dent* 2013;33:355–363.