

SUTURING FOR OPTIMAL SOFT-TISSUE MANAGEMENT

Lee H. Silverstein, DDS, MS; Gregori M. Kurtzman, DDS; Peter C. Shatz, DDS

Establishing nontension primary wound closure of various soft tissue flaps is paramount for optimal postsurgical wound healing. Surgical procedures that require clinical flap manipulation, such as those used with traditional periodontal therapy, periodontal plastic cosmetic surgery, hard and soft tissue regeneration, and the excision of pathologic tissue, also require excellence in execution. Also paramount to clinical success is a thorough understanding of the various techniques of surgery, suturing, and the materials currently available to ensure the desired clinical results. This article will discuss the rationale of specific suturing techniques and suture materials to help the clinician obtain optimal wound closure.

Key Words: surgery, suturing, technique, suture materials, suture needles, soft tissue, wound closure, wound healing

INTRODUCTION

The primary objective of dental suturing is to position and secure surgical flaps to promote optimal healing (Table 1). When used properly, surgical sutures should hold flap edges in apposition until the wound has healed enough to withstand normal functional stresses. When the proper suture technique is used with the appropriate thread type and diameter, tension is placed on the wound margins so primary intention healing occurs.¹ Accurate apposition of surgical flaps is significant to patient comfort, hemostasis, reduction of the wound size to be repaired, and prevention of unnecessary bone destruction. If surgical wound edges are not properly approximated and are therefore inadequate, hemostasis is present and blood and serum may accumulate under the flap, delaying the healing process by separating the flap from the underlying bone.²

During the closure portion of conventional peri-

odontal surgical therapy, the art of suturing allows for the precise positioning of the mucoperiosteal flaps. For instance, certain surgical procedures, such as an excisional new attachment procedure (ENAP) and modified Widman flap procedure, dictate that the surgical flaps be repositioned to their original position. Conversely, other periodontal procedures require that the surgical flaps be placed in either an apical, coronal, or lateral position, depending on the specific surgical objective of the procedure being performed.³

In periodontal plastic, cosmetic, and reconstructive procedures, choosing the appropriate suturing technique, thread type, thread diameter and surgical needle as well as using the proper surgical knot for each respective thread material chosen are all critical in obtaining optimal wound healing. This is especially true and challenging when tissues are coapted over hard and/or soft tissue, autologous or allograft material, and/or regenerative membranes. In addition, the art and precise skill of suturing is paramount to the success of all surgical procedures.¹

Lee H. Silverstein, DDS, MS, is an associate clinical professor in the Department of Periodontics, Medical College of Georgia, and is in private practice in Marietta, Ga.

Gregori M. Kurtzman, DDS, is a private practitioner in Silver Spring, Md.

Peter C. Shatz, DDS, is an assistant clinical professor in the Department of Periodontics, Medical College of Georgia, and is in private practice in Marietta, Ga. Address correspondence to Dr Shatz. (e-mail: thegumdoc@gmail.com)

SUTURE MATERIALS

Suture thread

The desired qualities of a suture thread include the tensile strength that is appropriate for its respective use, tissue biocompatibility, ease of tying, and

TABLE 1

General guidelines of suturing

- Sutures are usually placed distal to the last tooth, in each interproximal space, and suturing continues in a mesial direction.
- Sutures should always be inserted through the more mobile tissue flap first.
- When space is restricted use a ½ circle needle.
- Only needle holders should grasp suture needles, and the suture needle should be inserted and pulled through the issue in line with the circle.
- Grab the suture needle in the center of the needle, never at its tip or near where the thread is swag to the needle.
- The needle should be placed a few millimeters from the tip of the needle holder when grasped.
- The goal during suturing multiple tissue levels is to suture periosteum to periosteum and gingival tissue to gingival tissue.
- The needle should enter at right angles to the tissue when penetrating through tissues.
- Sutures should be placed no closer than 2 mm to 3 mm from the flap edges to prevent tearing through the flap during postoperative swelling.
- The flaps should be approximated without blanching when sutured.
- Pull the suture just tight enough to secure the flap in place without restricting the flap's blood supply.

allowance of minimal knot slippage. It is important that the clinician select the specific suture thread and diameter based on the thickness of the tissues to be sutured and whether tension-free mobile tissues are present or absent.⁴ Therefore, it seems that suture technique and material selection should be based on a knowledge of the desired goals of the respective surgical procedures and the physical and biologic characteristics of the suture thread in relationship to the intraoral in vivo healing process.

Practitioners have an armamentarium of suture materials from which to select for use both intraorally and extraorally (Table 2). Adequate strength of the suture material will prevent suture breakage, and proper suture knots for the material used will prevent untimely untying or knot slippage. Clinicians must also understand the nature of the suture material, the biologic processes of healing, the biologic forces in the healing wound, and the interaction of the suture and tissues. This is vital because practitioners must ensure that a suture will retain its strength until the tissues of the surgical flaps regain sufficient strength to keep the wound edges together. In those circumstances in which the intraoral tissues most likely will never regain their preoperative strength, or the surgical flaps are not tension free, clinicians should consider using a suture material that retains long-term strength for up to 14 days and resorbs in 21 to 28 days, such as conventional polyglycolic acid (PGA) sutures.^{2,4}

Conversely, if a suture is to be placed in a tissue

TABLE 2

Suture thread types used in dentistry*

A: Nonresorbable		
Type	Commonly used thread size	
Silk	3-0, 4-0, 5-0	
Nylon	4-0, 5-0, 6-0	
Polypropylene	5-0, 6,0	
e-PTFE	4-0, 5-0	
B: Resorbable		
Type	Commonly used thread size	Resorption time (days)
Gut	4-0	3-5
Chromic Gut	4-0, 5-0	7-10
PGA	3-0, 4-0, 5-0	21-28
PGA-dyed	3-0, 4-0, 5-0	21-28

*e-PTFE indicates expanded polytetrafluoroethylene; PGA, polyglycolic acid.

that heals rapidly (eg, intraoral tissue), clinicians should select a resorbable suture that will lose its tensile strength at about the same rate as the tissue gains strength. The suture will also be absorbed by the tissue so that no foreign material remains in the wound once the tissue has healed, such as surgical gut or the newer fast absorbing polyglycolic acid (PGA-FA).¹

Two mechanisms of absorption result in the degradation of absorbable sutures. First, sutures of biological origin, such as surgical gut (eg, plain and chromic gut), are gradually digested by intraoral enzymes.² This suture material is made from an animal protein and can potentially induce an antigenic reaction. When used intraorally, this material loses most of its tensile strength in 24 to 48 hours, unless it is coated with a chromic compound that extends absorption up to 7 to 10 days and extends loss of tensile strength for up to 5 days.⁵

Second, surgical gut sutures may break too rapidly to maintain flap apposition, particularly if used in patients with a very low intraoral pH. A decrease in intraoral pH may be caused by a plethora of physiological events, such as metabolic disorders (eg, epigastric reflux, hiatal hernia, bulimia). Autoimmunity caused by Sjögren's syndrome, chemotherapy, radiation therapy, and some medications (eg, maximum acid output inhibitors, angiotensin-converting inhibitors, antipsychotics, diuretics, antihypertensive agents, antipsoriasis medications, and steroid inhalers) can also result in dry mouth and a low intraoral pH.^{2,6}

The minimum coaptation time for tissue flaps is approximately 5 days.⁵ Therefore, clinicians should select a fast-absorbing PGA suture for indications in which there is a low intraoral pH, when surgical gut sutures are contraindicated. The PGA-FA suture

material is manufactured from synthetic polymers and is principally broken down by hydrolysis in tissue fluids in approximately 7 to 10 days; it is not affected by a low intraoral pH.^{1,2} The PGA-FA suture also has a higher tensile strength than surgical gut suture material; however, it absorbs at a rate comparable to that of surgical gut sutures under normal intraoral physiologic conditions.^{1,2}

Surgical threads, aside from being classified by the material they are made of, are also classified by thread diameter. Thread materials range in diameter from 1 to 10, and the higher number corresponds to the thinner, more delicate thread.⁷ With periodontal plastic surgery, a 5-0 thread diameter is most often used to secure soft tissue grafts and transpositional/sliding pedicle flaps, whereas a 4-0 thread is used to secure most other periodontal mucoperiosteal flaps. In implant dentistry, a 3-0 thread diameter is usually used to secure flaps when a mattress suturing technique is placed, and then a 4-0 thread is used closer to the flap edges to coapt the tension-free flap edges. A 4-0 thread is also used to secure implant surgical flaps when interrupted sutures, some mattress sutures, and most continuous suture techniques have been performed.

Surgical threads are also fabricated to be either natural or synthetic nonresorbable materials. Classically, silk has been the most universally used material in dentistry and many other surgical disciplines.⁸ Silk is easy to handle, ties with a slip knot, and is relatively inexpensive compared with other nonabsorbable suture materials currently available. However, silk has distinct disadvantages. First, it is nonabsorbable, so it must be removed, usually a week or so later when the patient is not numb. Second, silk specifically is a multifilament that "wicks" or pulls bacteria and fluids into the wound site.⁹ Therefore, silk is not the suture material of choice when any sterile materials are placed under a mucoperiosteal flap (eg, dental implant, bone graft, or regenerative barrier) or when there is clinical evidence of an infection at the surgical site. Instead of silk, other nonabsorbable sutures that can be used in these situations, such as nylon, polyester, polyethylene, polypropylene, or expanded polytetrafluoroethylene (e-PTFE).

Polyester sutures are made of multifilaments that are braided into a single strand. This suture is made of a polyethylene polymer, does not weaken when moistened, and has a lot of tensile strength. Polyester sutures are usually coated with a biologically inert nonabsorbable compound, which aids the suture in passing more easily through tissues. This coating, however, does present a problem in that it also makes

knot security an issue, because the material will easily untie if not secured with a surgeon's knot.⁴ The e-PTFE suture material is a nonabsorbable monofilament that has high tensile strength, good handling properties, and good knot security, but it is expensive compared with all the other nonresorbable suture materials.¹

Needles

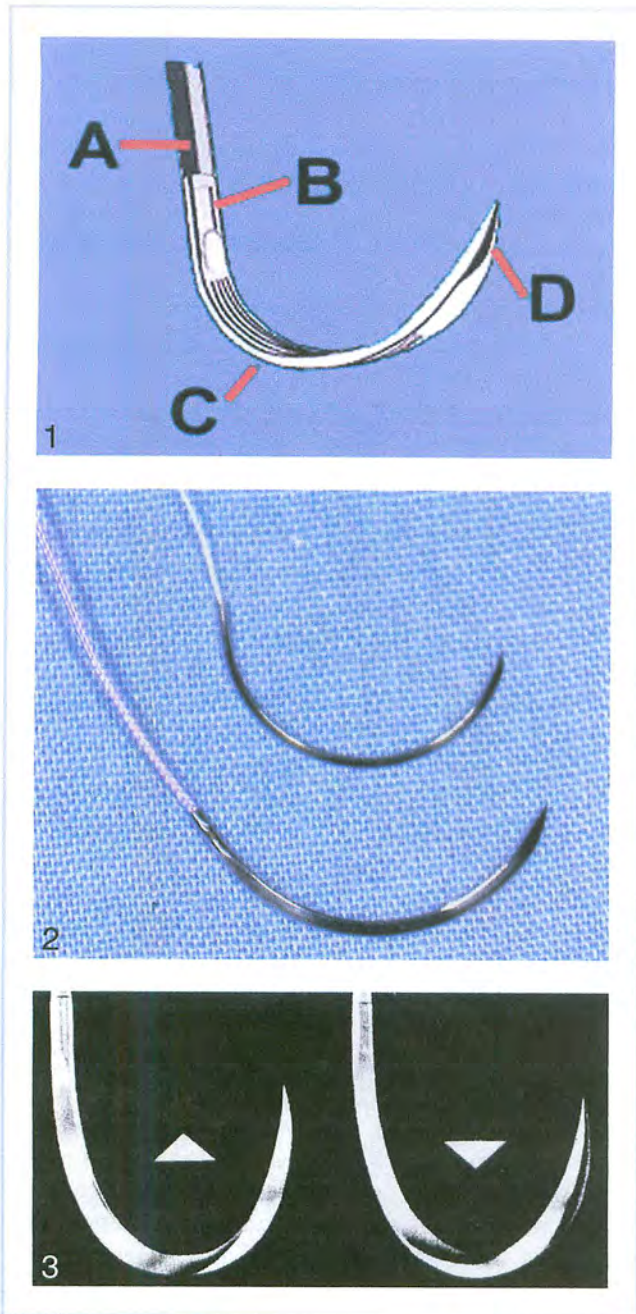
A surgical needle has 3 parts: the needle point, the needle body, and the swaged (press-fit) end (Figure 1). Suture needles are usually classified according to their curvature, radius, and shape.

The most commonly used suture needles in dentistry are the 3/8 and 1/2 circle needles^{3,4} (Figure 2). The 3/8 needle allows the clinician to pass from the buccal surface to the lingual surface in one motion by rotating the needle on a central axis. In contrast, the 1/2 circle needle is traditionally used in more restricted areas, for instance, in the buccal of the maxillary molars and the facial aspect of the maxillary and mandibular incisors. In addition, the 1/2 circle needle is routinely used for periosteal and mucogingival surgery.¹⁻⁴

Suture needles are also classified as either conventional cutting or reverse cutting⁵ (Figure 3). In dentistry, clinicians should always use reverse cutting sutures to prevent the suture material from tearing through the papillae or surgical flap edges, which is referred to as a "cut out." Usually, a cut out is caused by a conventional suture needle, because it has an inside concave curvature that is sharpened. A reverse cutting needle, on the other hand, has a smooth inner curvature, and its third cutting edge is located on its convex (outer) edge.⁴ Generally in dentistry, the 3/8 reverse cutting needle with a 3-0 or 4-0 thread diameter and the 1/2 reverse cutting needle with the thinner and more delicate 5-0 or 6-0 thread diameter are the most commonly used needle-and-thread combinations, in the author's experience.

Knots

Surgical knot tying is an important component to the art of suturing. For knot security and to prevent untimely knot untying, it is essential that the appropriate surgical knot be used for the specific suture material being secured. For instance, when using silk, e-PTFE, chromic gut, or plain gut suture material, a slip (granny) surgical knot should be used. However, with synthetic resorbable and other nonabsorbable synthetic suture materials, a surgeon's knot must be used to prevent untimely knot untying⁴ (Figures 4a through 4c). The type of knot that is used for each material is determined by the mode in which each type of thread is manufactured.⁵



FIGURES 1-3. FIGURE 1. Parts of the needle. A = thread, B = swag, C = body, D = point. FIGURE 2. Comparison of a 3/8 circle needle (bottom) and a 1/2 circle needle (top). FIGURE 3. Conventional cutting needle (left) and a reverse cutting needle (right).

USER-FRIENDLY SUTURING TECHNIQUES

The interrupted suture encompasses 2 suturing techniques: the simple loop and the figure-8. The simple loop (Figures 5 and 6) is the most commonly used technique in dentistry and is routinely used to coapt tension-free, mobile surgical flaps.⁴ For example, the simple loop is useful in edentulous ridge areas, to

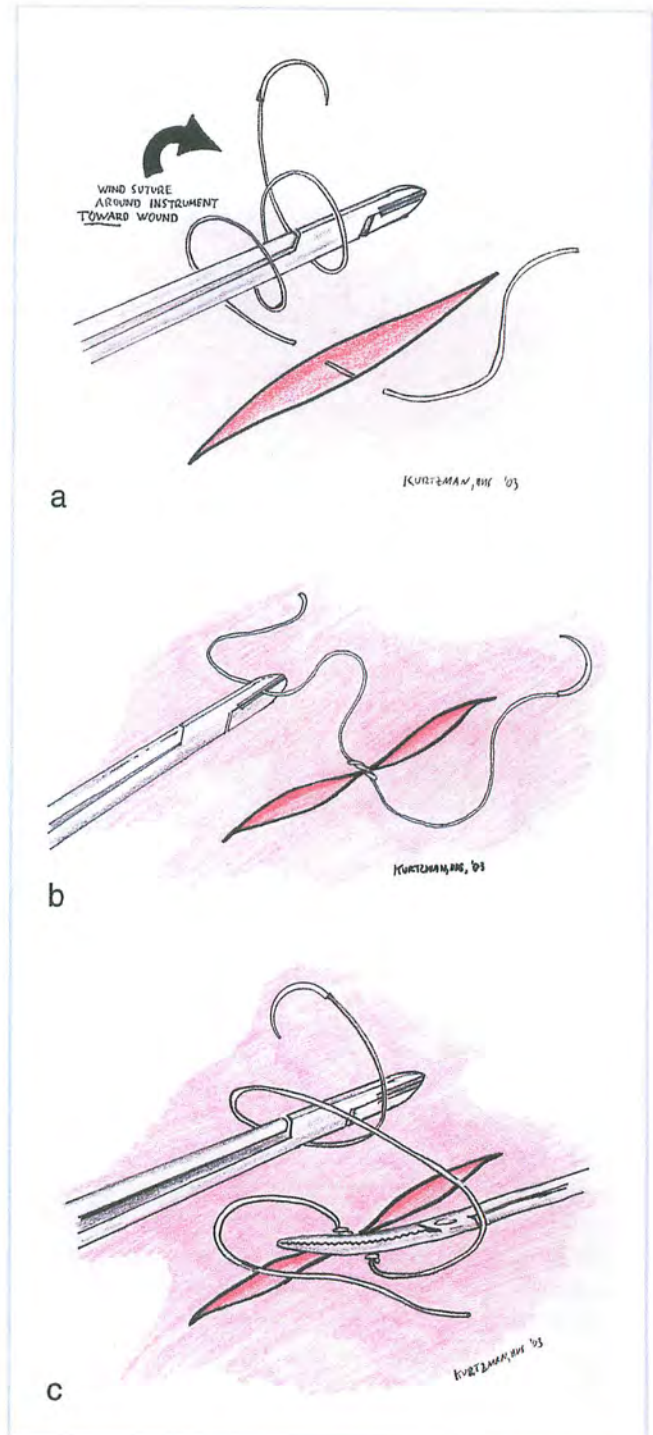


FIGURE 4. (a) Surgeon's knot, step 1: the suture needle is wound around the needle holder twice in the direction of the wound. (b) Surgeon's knot, step 2: the free end of the suture is grabbed with the needle holder and the knot is tightened to the tissue. (c) Surgeon's knot, step 3: the suture needle is wound around the needle holder once away from the wound, and then the free end of the suture is grasped and tightened, completing the knot.

coapt vertical releasing incisions, for periosteal suturing, and to coapt flaps in ENAP, modified Widman flap, some periodontal regeneration, and some exploratory flap procedures.

The figure-8 technique (Figure 7) is placed similarly to the simple loop on the buccal aspect; however, on the lingual aspect, the needle penetrates the outer, not inner, surface of the lingual flap. This results in the suture thread being interposed between the surgical flaps. Both interrupted suture techniques achieve similar results when used for wound closure with tension-free flaps. The figure-8 is useful when suturing on the lingual aspect of the lower molars, especially in a patient with an active gag reflex or a large, cumbersome tongue.⁴

Another suturing technique, which is a variation of the interrupted suture, is the mattress technique. This technique is usually used in areas where tension-free flap closure cannot be accomplished.⁴ Mattress suturing techniques are generally used to resist muscle pull, evert the wound edges (this keeps epithelium away from underlying structures), and adapt the tissue flaps tightly to the underlying structures (eg, bone graft, tissue graft, alveolar ridge, regenerative membrane, or dental implant). When using a mattress suture, usually a 3/8 reverse cutting needle is used with a thicker (3-0 or 4-0) thread diameter.¹ Traditionally, mattress sutures are left in place for 14 to 21 days before dissolution or removal.¹⁰

Variations of the mattress suture technique are referred to as the vertical (Figure 8), apically or coronally repositioned vertical mattress (Figure 9), vertical sling (Figures 10 and 11), and horizontal mattress (Figure 12). Unlike the mattress suture technique, interrupted sutures should be used only with tension-free mobile flaps and should have needle penetration 3 mm from the wound edges or at the base of an interdental papilla. In contrast, when performing a mattress suture, the needle penetration through the surgical flap should be about 8 mm away from the flap edge, or just coronal to the mucogingival junction, and always in keratinized tissue.

A horizontal mattress suture is tied (Figure 12) by penetration of the needle at the mesial buccal (position 1) apical to the mucogingival junction and crossed under the flap to exit at the mesial lingual (position 2). The suture then penetrates the tissue at the distal lingual (position 3) and again crosses under the flap to exit at the distal buccal (position 4) apical

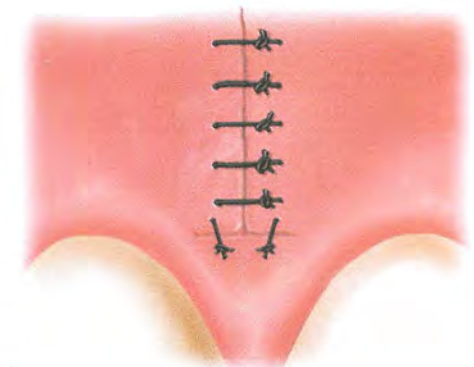
to the mucogingival junction. The suture at the distal buccal (position 4) is tied to the free end at the mesial buccal (position 1) (Figure 13).

The criss-cross technique is placed similarly to the simple loop on the buccal aspect; however, on the lingual aspect, the needle penetrates the outer, not inner, surface of the lingual flap. This results in suture thread being interposed between the surgical flaps. Both of the interrupted suture techniques achieve similar results when used for wound closure with tension-free flaps. The criss-cross is useful when suturing on the lingual aspect of the lower molars, especially in a patient with an active gag reflex or a large, cumbersome tongue.⁴ A criss-cross suture is tied (Figure 14) by entering the mesial buccal (position 1) and exiting the distal buccal (position 2). The suture is then crossed over the socket and enters the mesial lingual (position 3) and exits the distal lingual (position 4). The suture at the distal lingual (position 4) is tied to the free end at the mesial buccal (position 1), and the knot is positioned toward the buccal.

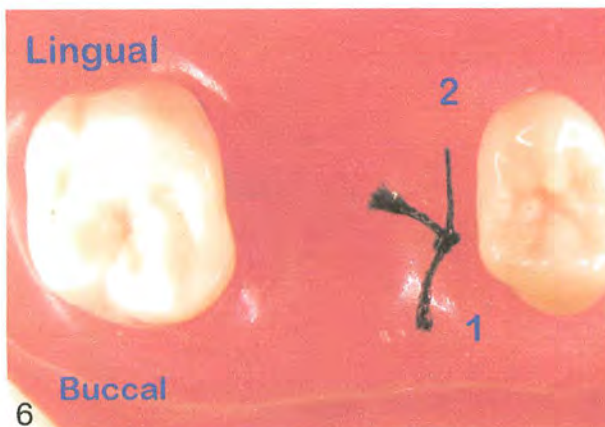
The interrupted suspensory suture, commonly referred to as the sling suture (Figures 10 and 11), is used when only 1 side, or 1 or more papillae of a flap, is independently repositioned to its original position or coronally repositioned. The sling suture technique is especially useful when performing coronally repositioned sliding flaps. When tying a sling suture, the needle enters the buccal flaps papilla mesially (position 1) and is carried lingually around the neck of the tooth or implant to penetrate the papilla distally (position 2) through the periosteum and exiting buccally. The suture is then looped back around the same tooth or implant lingually and is tied with the free end, positioning the knot buccally. With this suture technique, each suture involves a papilla on the mesial and distal of every other tooth using separate ties. A variation of this technique involves tying the suture on the lingual surface; it may be used when esthetic demands will not allow the surgical knot to be situated on the buccal surface (Figure 15).

Another variation of the interrupted suture technique is called a continuous suture. Continuous sutures can be used to attach 2 surgical flap edges (Figure 16) or to secure multiple interproximal papillae of one flap independently of the other flap. Although the distinct advantage of the continuous suture is that there are fewer individual suture ties, the disadvantages of using any continuous suture far outweigh the advantages of

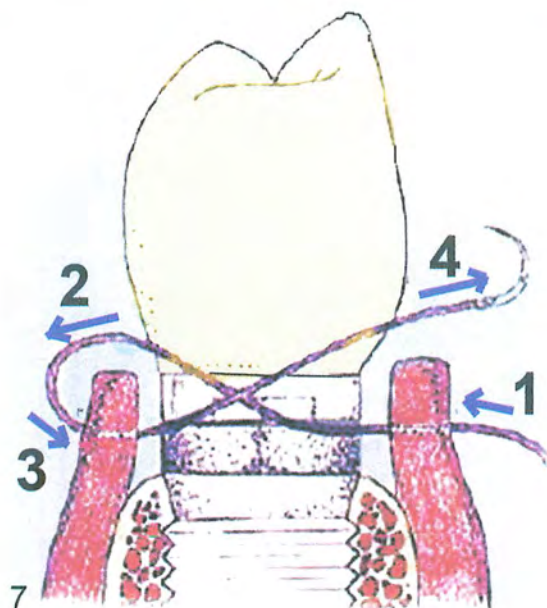
FIGURES 5-9. FIGURE 5. Simple suture. FIGURE 6. Simple suture. FIGURE 7. Figure-8 suture. FIGURE 8. Vertical mattress suture. FIGURE 9. Apically repositioned vertical mattress technique.



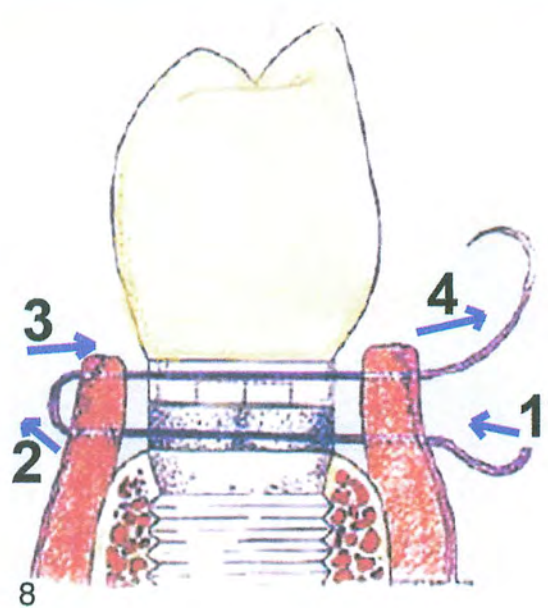
5



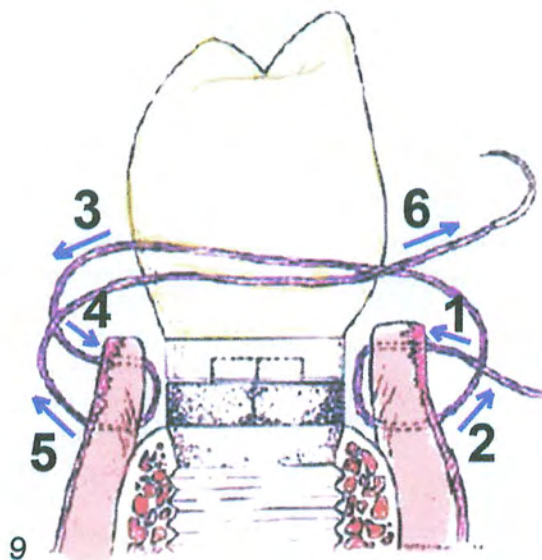
6



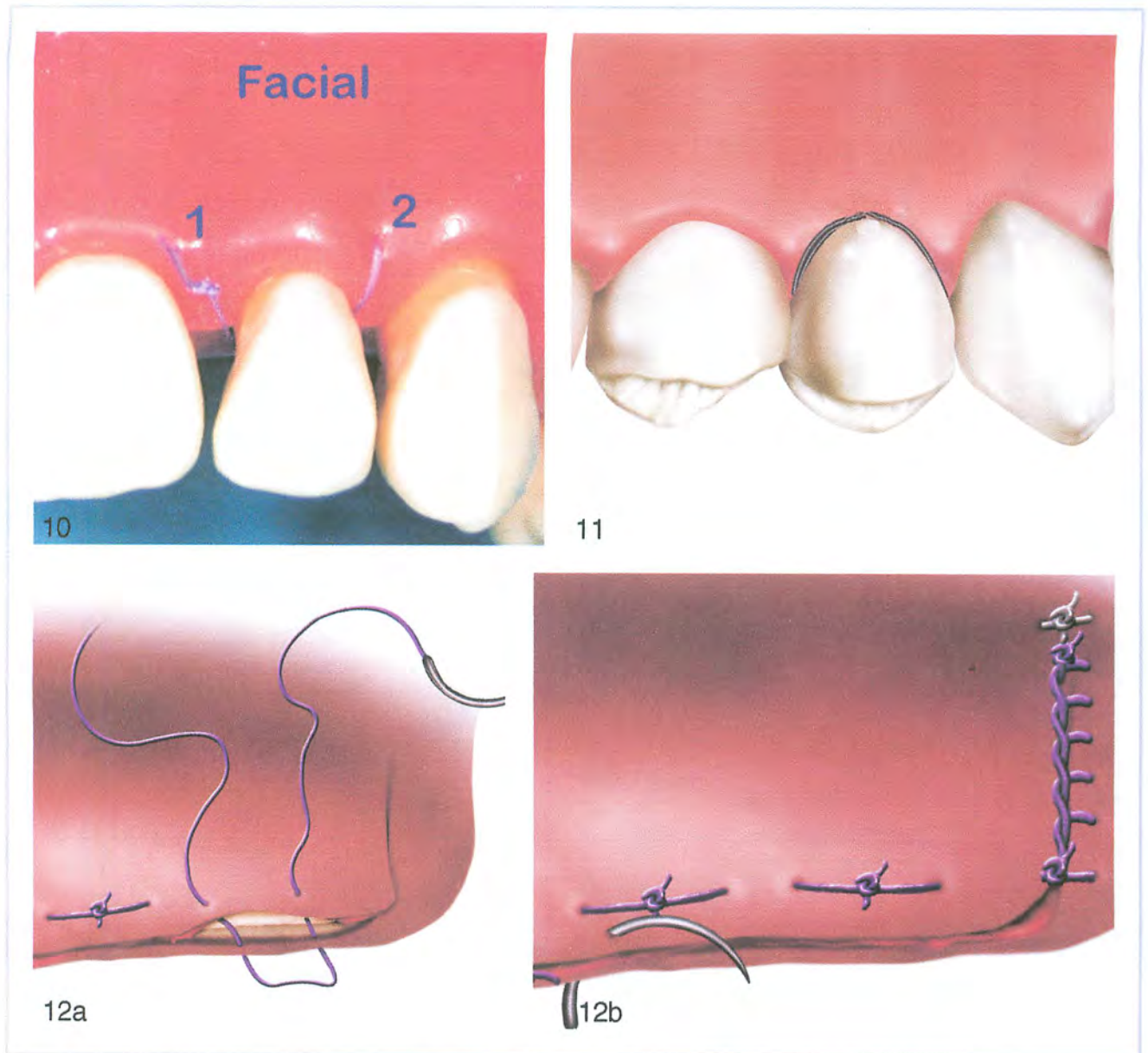
7



8



9



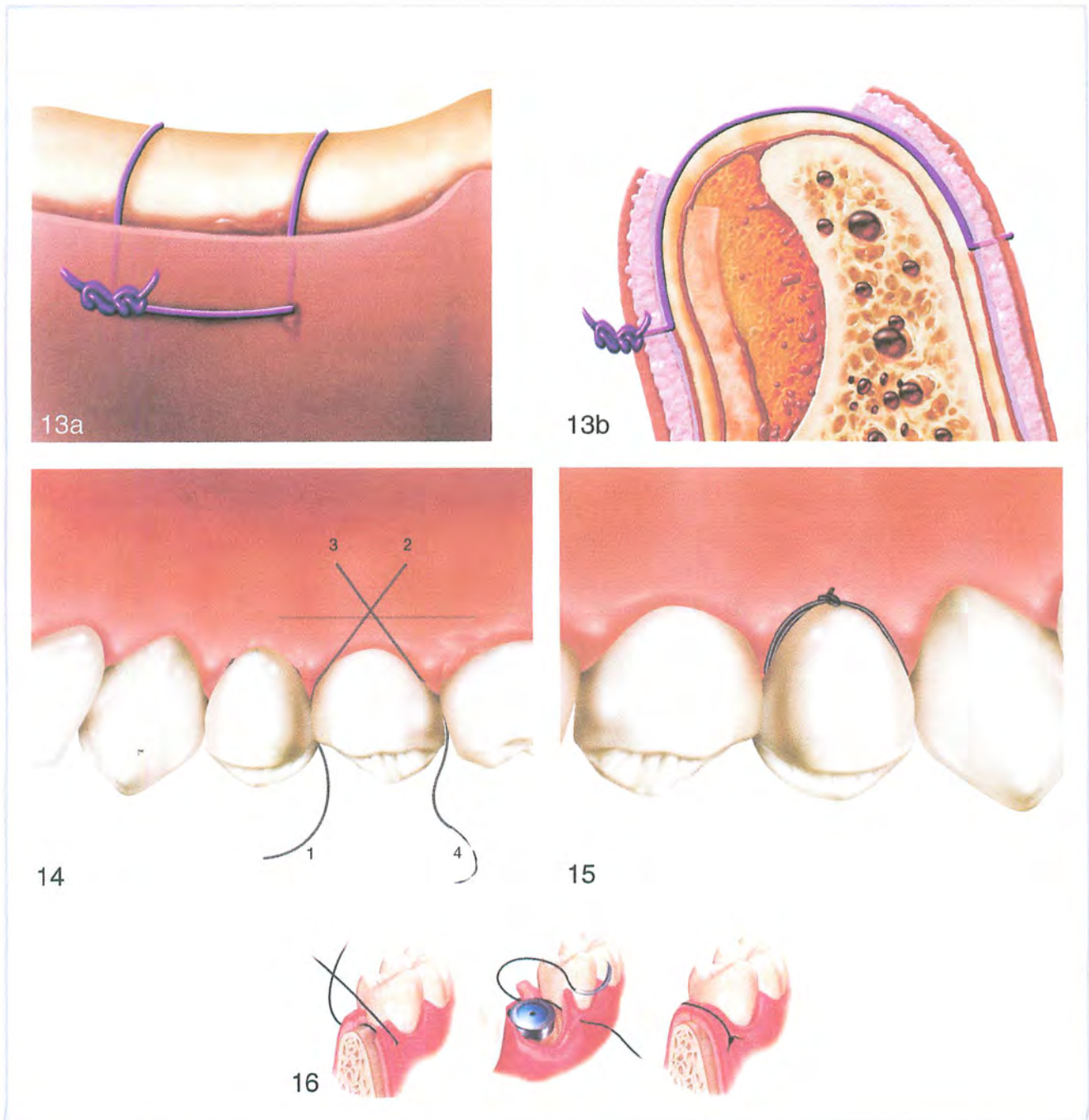
FIGURES 10-12. FIGURE 10. Buccal view of a sling suture. FIGURE 11. Lingual view of a sling suture. FIGURES 12a and 12b. Horizontal mattress suture illustrating the steps to tie this knot.

its use. This is due to the likelihood that if one knot or loop breaks, the integrity of the entire surgical site will become compromised.¹¹ Most clinicians would have more control using individually placed interrupted, sling, criss-cross, or mattress sutures in lieu of placing one large continuous suture.¹²

CONCLUSION

The evolution of suturing material has presented dentists with advancements in sutures designed for

specific surgical procedures. With the sophisticated surgical procedures used daily, there is a greater need for knowledge with regard to the various types of suturing armamentarium available to help obtain optimal wound closure.¹³ The success of technique-sensitive procedures such as conventional periodontal therapy, dental implant therapy, mucogingival microsurgery, periodontal cosmetic plastic surgery, regeneration of hard and/or soft tissue, and excisional treatment of pathologic tissue depends on the clinician's knowledge of and skill at executing proper suturing for optimal wound closure.¹³ The recent



FIGURES 13-16. FIGURES 13a and 13b. Horizontal mattress used to overcome muscle pull and prevent flap opening prematurely. FIGURE 14. Criss-cross suture technique demonstrating the steps to tie this knot. FIGURE 15. Variation of the sling suture with placement of the knot on the lingual aspect for esthetic situations that will not allow knot placement on the facial aspect. FIGURE 16. Continuous suture used to coapt a long incision line.

innovations in suturing materials not only eliminate some of the difficulties previously encountered during surgical closure but also decrease the potential for postoperative infections.

ACKNOWLEDGMENT

Special thanks to David Kurtzman, DDS, a cosmetic dentist located in Marietta, Georgia, for his beautiful illustrations.

REFERENCES

1. Silverstein LH. Essential principles of dental suturing for the implant surgeon. *Dent Implantol Update*. 2005;16:1-7.
2. Silverstein LH. Suture selection for optimal flap closure and tissue healing. Perio-implant showcase. *Pract Perio Aesthet Dent*. 2005;16:2-3.
3. Cohen ES. Sutures and suturing. In: *Atlas of Cosmetic Reconstructive Periodontal Surgery*. 2nd ed. Philadelphia: Lea & Febiger; 1994:9-30.
4. Silverstein LH. *Principles of Dental Suturing: The Complete Guide to Surgical Closure*. Mahwah, NJ: Montage Media; 1999.
5. Wound Closure Manual. Somerville, NJ: Ethicon; 1985:1-101.
6. Lilly GE, Salem JE, Armstrong JH, et al. Reaction of oral tissues to suture materials. *Oral Surg Oral Med Oral Pathol*. 1969;28:432-438.
7. Meyer RB, Antonin CJ. A review of suture materials, part I. *Compend Contin Educ Dent*. 1989;10:260-264.
8. Macht SD, Krizek TJ. Sutures and suturing—current concepts. *J Oral Surg*. 1978;36:710-712.
9. Manor A, Kaffe I. Unusual foreign body reaction to a braided silk suture: a case report. *J Periodontol*. 1981;53:86-88.
10. Mejias JE, Griffin TJ. The absorbable synthetic sutures. *Compend Cont Educ Dent*. 1983;4:567-572.
11. Hutchens LH. Periodontal suturing: a review of needles, materials and techniques. *Postgrad Dent*. 1995;2(4):1-15.
12. Silverstein LH, Kurtzman GM. A review of dental suturing for optimal soft-tissue. *Manage Compend*. 2005;26:163-171.
13. Kurtzman GM, Silverstein LH, Shatz PC, Kurtzman D. Suturing for surgical success. *Dent Today*. 2005;24(10):96-103.