

JOEL L. ROSENLICHT, DMD

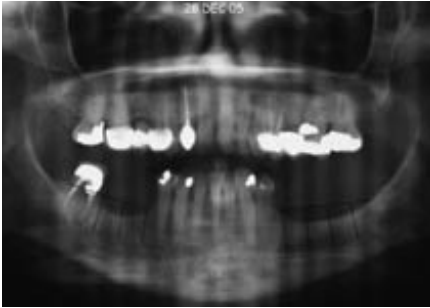


Fig 1

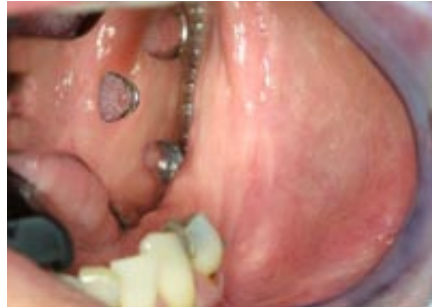

Fig 2

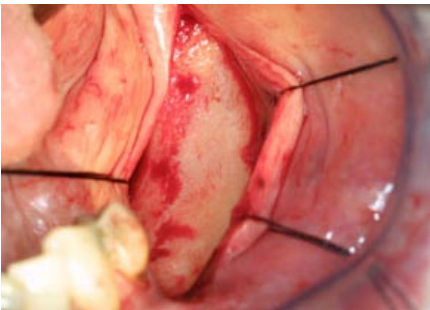


Fig 3

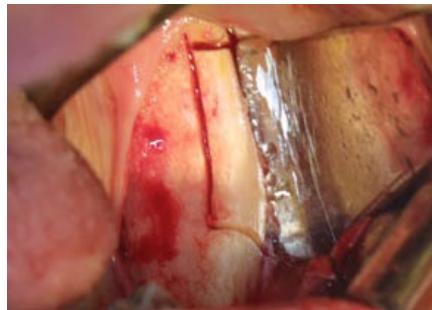

Fig 4

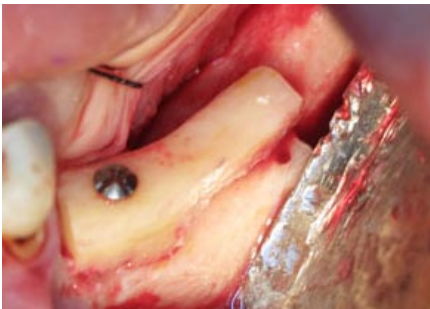

Fig 5

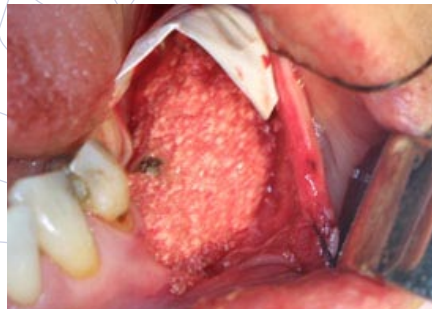

Fig 6

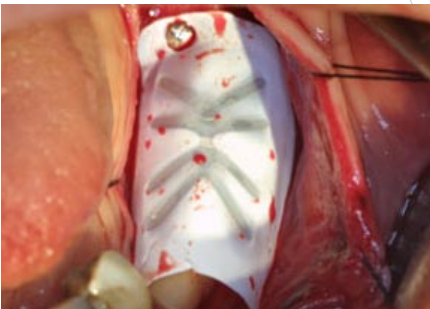


Fig 7

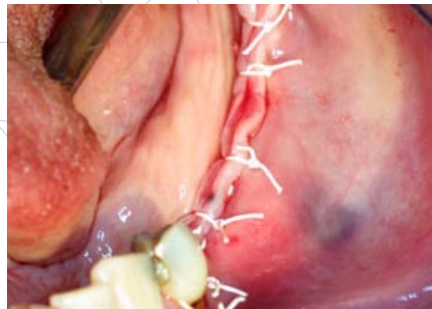

Fig 8

This case illustrates the use of a titanium-reinforced high-density PTFE membrane in conjunction with a corticocancellous block graft.

The preoperative evaluation revealed inadequate height and width for the placement of endosseous implants (Fig 1 and 2). The ridge was exposed with a mid-crestal incision and elevation of a full-thickness mucoperiosteal flap (Fig 3).

A corticocancellous block was harvested from the left ramus (Fig 4) and secured to the deficient alveolar ridge with titanium screws (Fig 5). The gap between the block graft and the ridge was augmented with allograft bone (Fig 5), then covered with a high-density titanium-reinforced PTFE membrane (Cytoplast® Ti-250 Posterior Large) (Fig 6 and 7).

Tension-free primary closure was achieved with a 3-0 PTFE suture (Cytoplast® PTFE Suture; CS0518) (Fig 8).

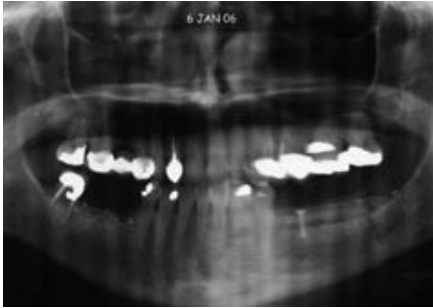


Fig 9

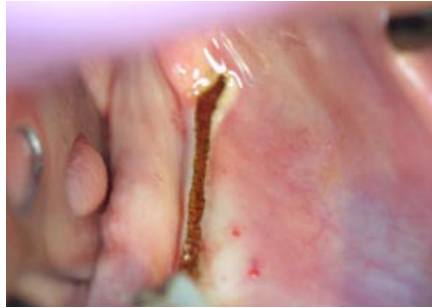

Fig 10

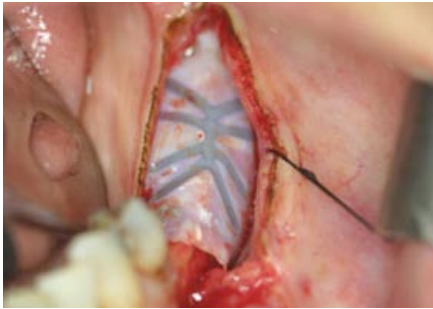


Fig 11

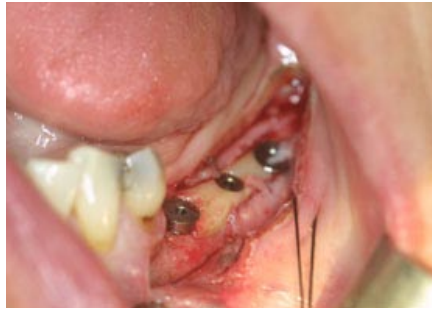

Fig 12

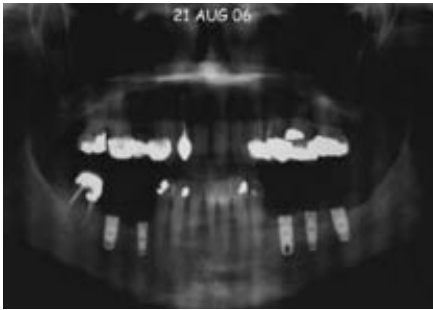


Fig 13

The postoperative panoramic radiograph demonstrates the increased alveolar height achievable with this technique (Fig 9).

8 months later, the membrane was exposed with a mid-crestal incision. (Fig 10 and 11). Compared to expanded PTFE membranes, removal of the dense PTFE membrane is greatly simplified due to the limited soft tissue ingrowth and attachment to the barrier.

An increase in ridge height and width was achieved allowing placement of implants into ideal position (Fig 12 and 13).

Cytoplast® is a registered trademark of Osteogenics Biomedical, Inc.

© 2009 Osteogenics Biomedical, Inc.
BBJJ0607

